

Association of Technical Personnel in Ophthalmology (ATPO)

CE on the Internet Article

This article and accompanying quiz are worth 1 JCAHPO Group A continuing education credit.

CONTINUING EDUCATION CREDITS ARE SUBJECT TO CHANGE. Internet Articles are reviewed on a regular basis for content and amount of time needed to complete the article and quiz. We advise you to print the article and take the quiz within 30 days. Ample notice is provided when CE credits change - please check the Web site frequently for any updates and/or changes. We will accept articles for full credit within a 30-day time period when CE credits have changed or when an article has been removed from the Web site.

MULTIPLE ETIOLOGIES OF BLURRY VISION

Aaron Shukla, PhD, COMT

ABSTRACT

This review paper discusses the role of the human eye in producing optimal images, and describes how images can be degraded resulting in symptoms of blurry vision.

The role of the human eye is to create a sharp image on the retina by using an appropriate amount of positive vergence (plus power) supplied by the air-tear-cornea refractive interfaces and the crystalline lens. The inverted and flipped retinal image is then transmitted for processing to the visual cortex. Factors that reduce the sharpness of an image created on the retina resulting in symptoms of blurry vision include: variations in refraction and scattering of light, alterations to retinal architecture, ocular tissues affected by pathology and disease, inflammation, and trauma.

The human eye can only provide the proper amount of positive vergence when all the individual ocular tissues that refract light are functioning optimally. Tear film abnormalities and irregular astigmatism can decrease sharpness of retinal images thus producing blurry vision.

Reduction of image quality can also result from scattering, which depends on the wavelength of light: longer wavelengths (e.g., red) scatter less, whereas shorter wavelengths (e.g., blue) scatter more. Corneal disease, dystrophy, or degeneration whether stromal, epithelial, or endothelial, can cause blurry images because all these conditions scatter light rays.

Blurring of images can result from any disease or condition that alters normal retinal architecture, thus interfering with normal transformation of light signals into electrical signals. Examples include retinopathy, traction on the retina, lattice defects in the retina, retinal undulations producing metamorphopsia, ischemic or scarred retina resulting in a scotoma, and retinal tears and detachments involving the fovea and extra-foveal regions.

Image quality can be degraded by a variety of pathologies (e.g., trachoma, and viral keratitis) and diseases (e.g., cataracts, neurological diseases, and glaucoma) because they alter the optimal vergence and optics of refractive ocular surfaces. Blurry vision generally results when the path of light rays is markedly changed.

Inflammation represents the third level of defense by the body against tissue compromise and can occur in many ocular structures thereby causing inflammatory diseases such as dry eyes, keratitis, anterior uveitis, vitritis and retinitis, and optic neuritis. Inflammatory diseases can deteriorate retinal images and produce blurry vision.

Injury to ocular tissues can reduce or eliminate their ability to refract light appropriately, thus reducing image quality and producing blurry vision. Examples of trauma that can produce blurry vision include: chemical burns, penetrating injury, retinal detachment, blowout fractures, and lid lacerations.

I. INTRODUCTION: ROLE OF THE HUMAN EYE AND FACTORS THAT REDUCE VISION

This paper reviews the role of the human eye in producing optimal images, and discusses how images can be degraded resulting in symptoms of blurry vision.

The role of the human eye is to create a sharp image on the retina by using an appropriate amount of positive vergence (plus power) supplied by the air-tear-cornea refractive interfaces and the crystalline lens (Table 1). The inverted and flipped retinal image is then transmitted for processing to an area in the occipital lobe of the brain termed the striate complex, Brodmann area 17, or the visual cortex (Cassin, 1995).




Table 1: Refractive Power of Ocular Surfaces

■ R.I.	Tears	1.336
	Cornea	1.376
	Lens	1.386
■ Radius of Curvature	Anterior K	7.7 mm
	Posterior K	6.8 mm
	Anterior Lens	10.0 mm
	Posterior Lens	6.0 mm
■ Refracting Power	Air-Tear	+43.6 D
	Tear-Ant. K	+5.3 D
	Post. K-Aq.	-5.8 D
	Lens w/o acc.	+19.1 D
	Lens w/ acc.	+33.0 D
■ Refractive Power	Air- Ant K	+48.8 D (Blurry)

Stein et al., 2000; Thall et al., 2000

Snellen visual acuity (VA) measures central vision and the ability to perceive an image that subtends an angle of 5 minutes ($5'$) of arc on the retina. Each line or space of a Snellen optotype is $1/5^{\text{th}}$ this size, or $1'$. Based on retinal anatomy, *i.e.*, spatial arrangement of cells in the nerve fiber layer (NFL), the minimal angle of resolution (MAR), or the greatest resolving power of the eye, is approximately $30''$ of arc corresponding to a VA of 20/10. Perceiving an image that subtends an angle of $1'$ of arc corresponds to a VA of 20/20 (Cassin, 1995).

A decrease in VA can be correlated with a decrease in visual function, as shown below (Table 2):




Table 2: Loss of Visual Function

- 20/20 = 100% visual function
- 20/50 = 25% loss of visual function
- 20/100 = 50% loss of visual function
- 20/400 = 90% loss of visual function

(Faye, 2000)

Many factors can reduce the sharpness of an image created on the retina, resulting in symptoms of blurry vision (Table 3).




Table 3: Factors that Reduce Image Sharpness

- Refraction variations
- Scattering
- Retinal variations
- Pathology and diseases
- Inflammation
- Trauma

II. REDUCTION OF IMAGE QUALITY BY VARIATIONS IN THE REFRACTION OF LIGHT

The human eye can only provide the proper amount of positive vergence (plus power) when all the individual ocular tissues that refract light (providing +ve vergence) are functioning optimally. Table 4 lists some of the factors that decrease sharpness of retinal images thus producing blurry vision.



Table 4: Reduction of Image Quality by Variations in Refraction of Light

- Tear film variations
- Irregular astigmatism

Tear Film Variations

Two principal factors that play a role in altering the path of light rays entering the eye and provide +ve vergence (plus power) are: change of refractive index (R.I.) across an interface and the radius of curvature of a refracting surface (Fig. 1). Thus, the power of a curved refracting surface is equal to the difference in R.I. of the media (n_2 = medium into which light is entering; n_1 = medium from which light is coming) and the radius of curvature (in meters) of the refracting surface. An example of +ve vergence (plus power) is the anterior surface of the cornea, whereas an example of -ve vergence (minus power) is the posterior surface of the cornea.

As shown in Fig. 1, the air-tear-cornea refractive interfaces provide approximately 43 D (diopters) of net refractive power, with the crystalline lens providing approximately 19 D, for a total of approximately 62 D of refracting power of the human eye. This corresponds to a total magnification of approximately 15x (Stein et al, 2000; Thall et al., 2000).

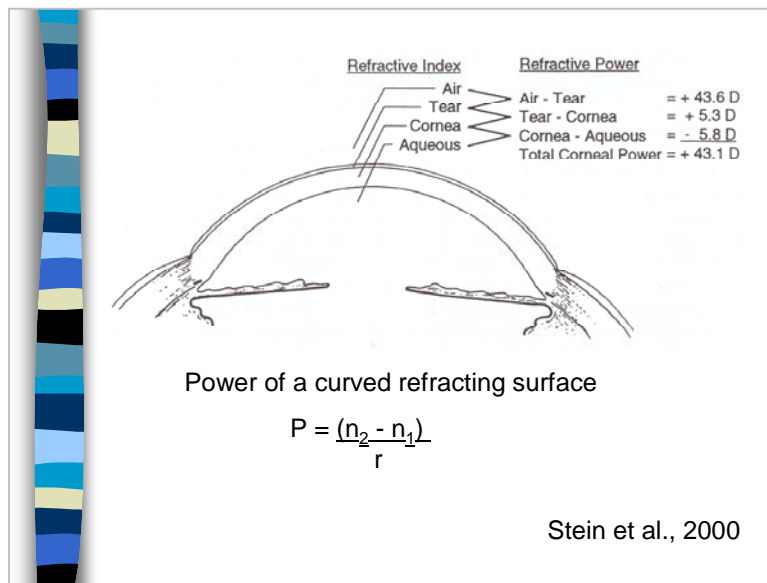


Figure 1: Refractive power of the air-tear-cornea interfaces

In addition to providing O_2 , nutrition, and immune responses, a normal tear film is necessary for the proper optical functioning of the cornea. The mucus layer smoothes epithelial irregularities, the aqueous layer provides the first major +ve vergence (plus power) at the air-tear interface, and the oil layer prevents rapid evaporation of the aqueous layer. In a dry eye a proper air-tear interface is absent and thus no +ve vergence (plus power) is imparted to light rays, thus producing a blurry image.

Even though the cornea has the appropriate R.I. (1.376) and anterior radius of curvature (7.7 mm) to provide approximately 48.8 D of +ve vergence

$$\left\{ \frac{1.376 - 1.000}{0.0077} \right\}$$

this convergent light will be

scattered by the irregular surface of the corneal epithelium. Thus, as a practical optical matter, a "tearless" cornea will not be able to produce a single clear image despite providing 48.8 D of +ve vergence.

Irregular Astigmatism

A cornea with normal optical properties may display regular astigmatism characterized by a normal retinoscope reflex. Such a cornea can be represented by one optical (power) cross with its axes aligned at 90° to each other (Fig. 2A). This optical condition can be readily corrected with spherocylinder spectacle lenses, toric soft contact lenses, or spherical rigid gas permeable contact lenses, all of which can produce one sharp image.

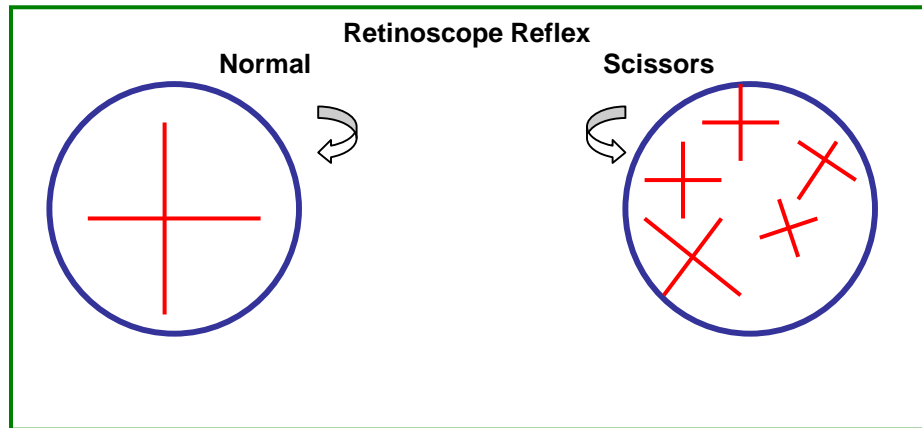
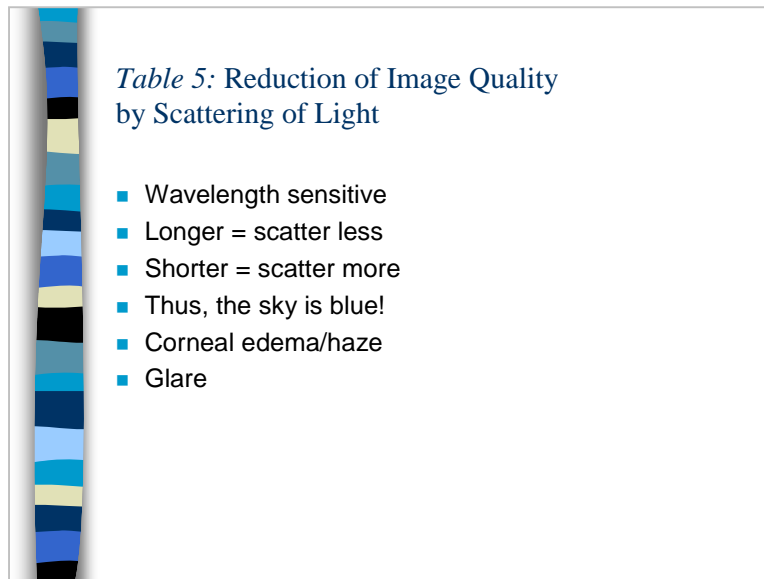


Figure 2: Optical (power) crosses depicted for regular (A) and irregular (B) corneal astigmatism

In contrast, a cornea displays irregular astigmatism and a scissors retinoscope reflex when small areas of the cornea have their own independent astigmatic axes and powers, all of which vary over a large part of the cornea (Fig. 2B) (Thall et al., 2000). This optical condition cannot be corrected with spherocylinder spectacle or soft contact lenses because those optical devices only produce one sharp image which will be degraded by other blurry images. However, irregular astigmatism can be corrected with spherical rigid gas-permeable contact lenses, because they eliminate the anterior corneal surface (with irregular astigmatism) as a refractive surface.

III. REDUCTION OF IMAGE QUALITY BY SCATTERING OF LIGHT

Scattering of light depends on the wavelength: longer wavelengths (e.g., red) scatter less, whereas shorter wavelengths (e.g., blue) scatter more, which explains why the sky is blue (Table 5).



Corneal disease, dystrophy, or degeneration whether stromal, epithelial, or endothelial, can cause blurry images because all these conditions can scatter light rays (Fig. 3).

The corneal epithelium is prone to disease and injury, but rapidly regenerates. Most of corneal thickness is due to the stroma which is composed of 200 – 250 evenly spaced collagen lamellae that are oriented at 90° to each other (Stein et al., 2000). This even spacing allows appropriate refraction of light rays. Any condition (e.g., corneal edema) that disrupts this even spacing will cause scattering of light and production of blurry images. Corneal conditions that cause blurry images include granular corneal dystrophy (Fig. 3A), band keratopathy (Fig. 3B), and *Herpes simplex* keratitis (Fig. 3C).

Other disease conditions that produce a blurry image by scattering light include:

- anterior uveitis (iritis) in which cells (leukocytes) and flare (protein) in the anterior chamber produce glare by scattering light
- cataracts in which hardening of the lens (nuclear sclerosis), areas of hydration (cortical), or areas of epithelial growth (posterior subcapsular) produce glare by scattering light
- vitritis in which a hazy vitreous produce glare by scattering light
- retinal edema in which collection of serum scatters light

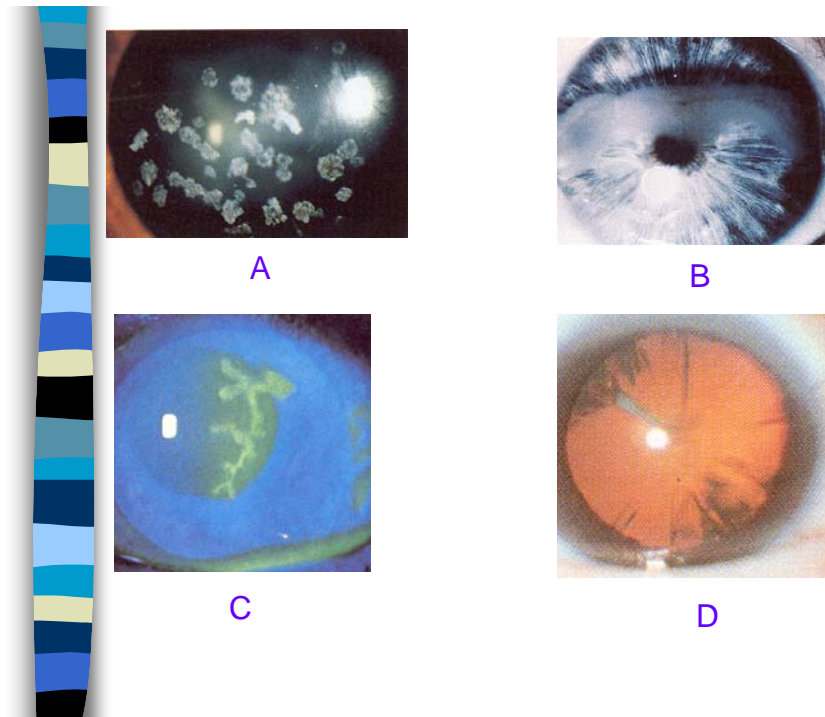


Figure 3: Diseases producing blurry images by scattering light. Corneal defects. (A) granular corneal dystrophy; (B) band keratopathy; and (C) *Herpes simplex* keratitis. (D) cortical cataract (Stein et al., 2000).

IV. REDUCTION OF IMAGE QUALITY BY VARIATIONS IN RETINAL ARCHITECTURE

Blurring of images can result from any disease or condition that changes normal retinal architecture (Table 6), e.g., retinopathy, traction on the retina, lattice defects in the retina, retinal undulations producing metamorphopsia, ischemic or scarred retina resulting in a scotoma, and retinal tears and detachments involving the fovea and extra-foveal regions (Fig. 4).

<i>Table 6: Reduction in Image Quality by Variations in Retinal Architecture</i>	
■	Retinopathy
■	Traction
■	Lattice
■	Metamorphopsia
■	Scotoma
■	Tears & detachments
■	Vascular events

Retinopathy

Retinopathy resulting in blurry vision can have many causes. Hypertension can result in marked arteriolar attenuation and hemorrhages all of which cause blurring of images (Fig. 4A) (Sanders & Graham, 2000). Age-related macular degeneration (ARMD) is the leading cause of blindness over the age of 50, and is a progressive disease whose end stage is permanent loss of central vision due to scarring (Hardy & Crawford, 2000) (Fig. 4B). Diabetic retinopathy can cause blurring of images due to a variety of causes, e.g., intraretinal serum leakage causing macular edema, retinal hemorrhages, and retinal detachments (Fig. 4C). Variations in uncontrolled blood glucose can cause 3 to 4 diopters of vergence changes (myopia or hyperopia) and pronounced blurring of retinal images (Sanders & Graham, 2000).

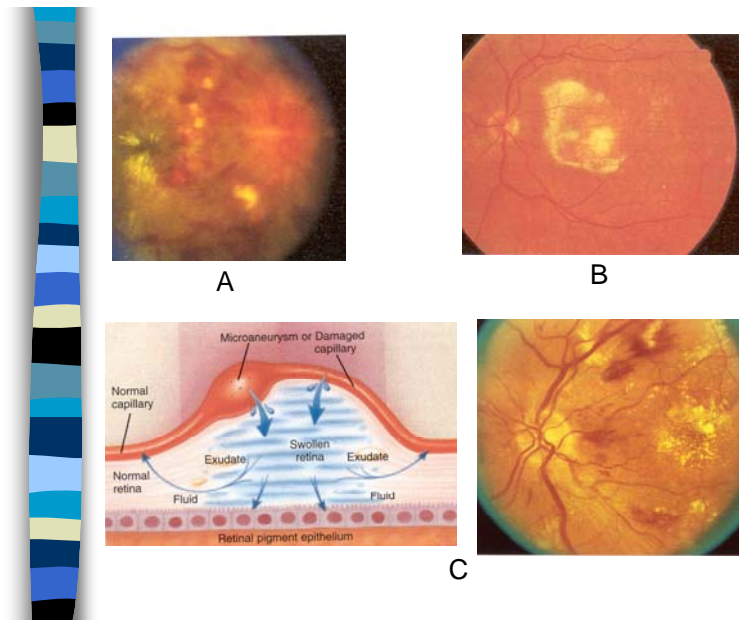


Figure 4: Examples of changes in retinal architecture. Hypertensive retinopathy (Stein *et al.*, 2000); Age-related macular degeneration (Flynn *et al.*, 2000); Mechanism of microaneurysms produced by diabetic retinopathy (left), and fundus photo showing microaneurysms (right) (Flynn *et al.*, 2000).

Traction

Traction by the vitreous pulls the neurosensory retina away from the retinal pigment epithelium (RPE). This is very common in diabetic retinopathy in which the retina is pulled anteriorly (Hardy & Crawford, 2000), thus resulting in blurring of images (Fig. 5 A).

Lattice

Lattice degeneration is a vitreo-retinal abnormality in which the internal limiting membrane is discontinuous and may be accompanied by liquefied vitreous (Flynn *et al.*, 2000). Lattice degeneration is commonly seen in myopia, and may be associated with retinal tears and detachments (Hardy & Crawford, 2000).

Metamorphopsia

Metamorphopsia is the perception of distortion in objects that normally should be straight, e.g., poles, door frames, and buildings. Distortion is most commonly due to choroidal neovascularization with associated membranes (Fig. 4B) (Hardy & Crawford, 2000).

Scotoma

An absolute scotoma is a non-seeing area in the visual field that cannot be seen with a larger and brighter stimulus, and is most commonly produced by tears, detachments, holes, and vascular events in the retina (Fig. 5).

Retinal Tears and Detachment

Retinal tears are caused by acute vitreous collapse (O'Malley, 2000) and, since they are generally located anterior to the equator, may not cause blurry vision (Fig. 5B). Such tears, however, may result in a rhegmatogenous retinal detachment associated with vitreous hemorrhage (O'Malley, 2000). Retinal detachment is defined as separation of the neuro-sensory retina from the retinal pigment epithelium, resulting in loss of vision that is commonly described as a descending or ascending curtain of darkness. An ascending curtain from the inferior visual field is caused by a detachment of the superior retina (Fig. 5B), and is more serious because the detachment can rapidly progress downward due to gravity and affect the macula ("macula-on" retinal detachment). A descending curtain from the superior visual field is caused by a detachment of the inferior retina, and may not involve the macula ("macula-off" retinal detachment). A macula hole is a partial or full thickness absence of neuro-sensory retina in the macula due to which central vision may be blurry (Fig. 5C) (Hardy & Crawford, 2000).

Vascular Events

Vascular events in the retina, *e.g.*, occlusion of arteries and veins, can cause a sudden loss of vision and constitute an ocular emergency. Central retinal artery occlusion (CRAO) is caused by a blockage in the artery serving the inner layers of the retina due to which the nerve fiber layer appears ischemic. Since only one-layer of ganglion cells is present in the fovea, a red reflex from choroidal blood will appear as a cherry-red spot located in the fovea (Fig. 5D) (Hardy & Crawford, 2000). Common causes resulting in CRAO include cholesterol (Hollenhorst) plaques and calcific plaques from heart valves. CRAO is an ocular emergency which can result in irreversible damage to the retina and loss of vision if ischemia persists for more than 90minutes (Hardy & Crawford, 2000). Immediate therapy can include increasing blood CO₂ levels, by breathing into a paper bag, which causes blood vessels to dilate thus moving the occlusive plaque to more distal vessels. A central retinal vein occlusion (CRVO) can result from a normal arterial supply accompanied by an occlusion in the central retinal vein due to which the arterial blood is not able to exit the eye. This results in extensive retinal hemorrhages (Fig. 5E) and a painless loss of vision.

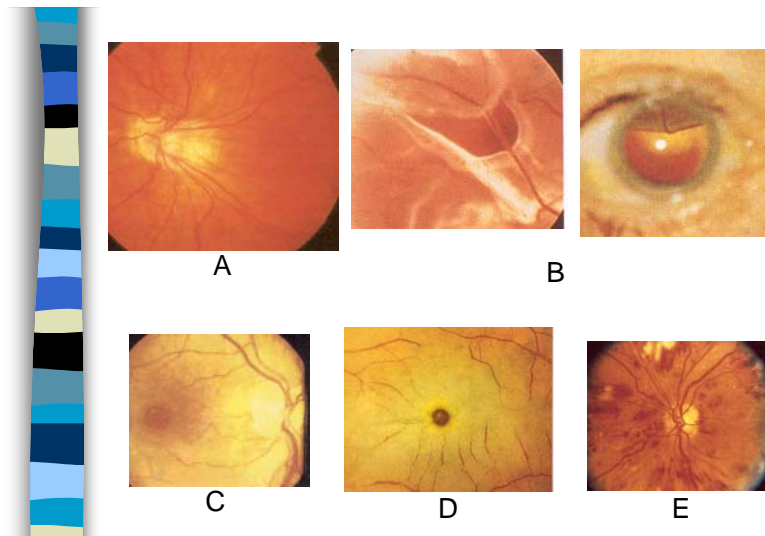
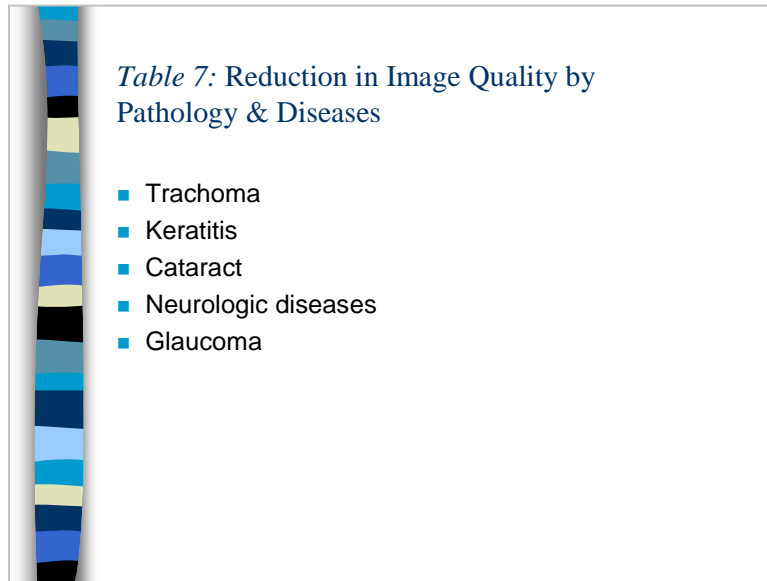


Figure 5: Changes in retinal architecture producing blurry images. (A) Traction on the retina by vitreous (BCSC, 2000); (B) Horse-shoe retinal tear (left) and retinal detachment (right) (Stein et al., 2000); (C) Macular hole (Stein et al., 2000); (D) Cherry red spot due to a central retinal artery occlusion (Stein et al., 2000); (E) Hemorrhages due to a central retinal vein occlusion (Stein et al., 2000)

V. REDUCTION OF IMAGE QUALITY BY PATHOLOGY AND DISEASES

Infectious and noninfectious diseases can degrade the quality of a retinal image thus producing blurry vision (Table 7).



Trachoma

Trachoma is a chlamydial infection caused by *Chlamydia trachomatis* and is the leading cause of preventable blindness in the third world, and the second leading cause of blindness worldwide (Cantor *et al.*, 2000). An infection results in keratoconjunctivitis which, if not treated, typically results in a neovascular membrane growing over the conjunctiva, limbus and cornea. This membrane prevents adequate amount of light from entering the eye in order to create an appropriate retinal image. Trachoma is easily prevented by practicing proper hygiene, and can be treated by drugs following an infection.

Keratitis

Keratitis is an inflammation of the cornea, but may also include the conjunctiva. In general, when the cornea is involved the patient will complain of blurry vision, pain (from corneal nerves), and photophobia (from painful dilation of iris vasculature) (Vaughan *et al.*, 2000). Corneal thickening due to edema or scarring will degrade the quality of retinal images, thus producing blurry vision. *Herpes simplex* virus (HSV) is a frequent cause of infectious keratitis usually involving the labial herpes virus, although the genital herpes virus can also be transferred to the eye. Typically, if the infection flares it will cause epithelial keratitis manifested by growth of dendrites with terminal bulbs (Fig. 3C). It is thought that following a primary infection through mucous membranes the virus travels down the trigeminal nerve and stays dormant in the nerve ganglion. When activated from a variety of causes, the virus travels to the corneal epithelium causing acute inflammation and formation of dendrites. Because the virus stays in the trigeminal ganglion, cross contamination may occur and a patient may present with herpes keratitis without having a primary infection in the eye. This is termed a “backdoor” infection and patients may have to be appropriately counseled (Schwab *et al.*, 1996).

Cataract

A cataract is an opacification of the crystalline lens causing light to scatter, thus degrading the quality of retinal images and producing blurry vision. Nuclear sclerotic cataracts (NSC) form in the center of the lens by compaction of old layers of the cortex as new layers are added just inside the lens capsule. The refractive index of the newly-formed nucleus increases from 1.386 (see Table 1) causing an increase in +ve vergence (plus power) of the total lens, and thus an increase in the total refractive power of the eye. When looking at distance the patient experiences a myopic shift and blurry vision, since the best image moves from the retina to the vitreous. The net result is that the patient, although presbyopic, can easily read at close without any correction (“second” sight). Cortical cataracts (CSC) are wedge-shaped areas of

hydration that “spoke” inward from the periphery (Fig. 3D) and cause glare and blurry vision. Posterior sub-capsular cataracts (PSC) are areas of new epithelial tissue that grow just internal to the posterior capsule and cause intense glare, blurry vision, and a pronounced loss of contrast.

Neurologic Diseases

Neurologic diseases, such as optic nerve diseases, can cause blurry vision by degrading the quality of light signals that are converted to electrical signals by photoreceptors, but are not adequately transmitted to the visual cortex because the optic nerve is not functioning optimally. The hallmarks of optic neuropathy include color vision defects, relative afferent pupillary defect, and changes in the visual field and optic disc (Table 8).

Table 8: Optic Nerve Diseases	
■	Clinical Signs
■	Relative Afferent Pupillary Defect
■	Color vision abnormalities
■	Visual field changes
■	Optic disc changes:
–	Optic disc swelling
–	Optic atrophy (nonspecific causes)
–	Optic disc cupping (glaucoma)
–	Optic disc pallor
–	Exudates
■	Disc pallor can be correlated with losses in visual acuity and visual field, and pupillary abnormalities.

Glaucoma

Glaucoma, the third leading cause of worldwide blindness after cataracts and trachoma, is an ill-defined disease characterized by optic disc changes with attendant visual field loss, for which intraocular pressure (IOP) is the main risk factor (Cantor *et al.*, 2000).

Figure 6 depicts the normal trabecular outflow of aqueous from the anterior chamber via the trabecular meshwork, and Schlemm’s canal. Small amounts of aqueous also exit via uveo-scleral outflow, utilizing the ciliary body and sclera, and entering episcleral flow.

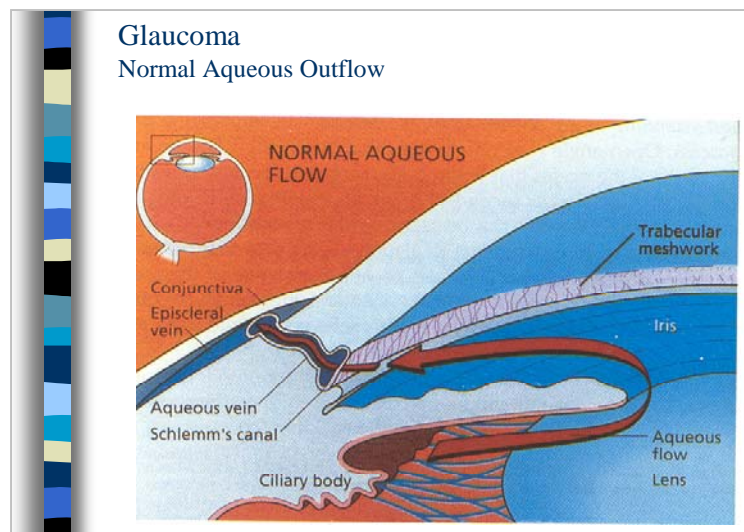


Figure 6: Schematic diagram showing normal aqueous outflow (from Cantor *et al.*, 2000)

Elevated IOP usually results from a disruption in the normal outflow of aqueous.

In open-angle glaucoma outflow of aqueous is compromised despite an open angle, thus indicating that some mechanism interferes with the normal flow of aqueous into Schlemm's canal. In angle-closure glaucoma IOP is suddenly elevated because the pupil blocks access to the trabecular meshwork (Fig. 7). Acute angle-closure glaucoma ("glaucoma attack") is an ocular emergency requiring immediate intervention. Symptoms of a "glaucoma attack" include blurry vision, pain, and photophobia, whereas signs include a "steamy" cornea due to epithelial edema, mid-dilated pupil, and acute conjunctival injection. Therapies include immediate reduction of IOP by laser peripheral iridectomy, oral diuretics, and IOP lowering topical medications (Cantor *et al*, 2000)

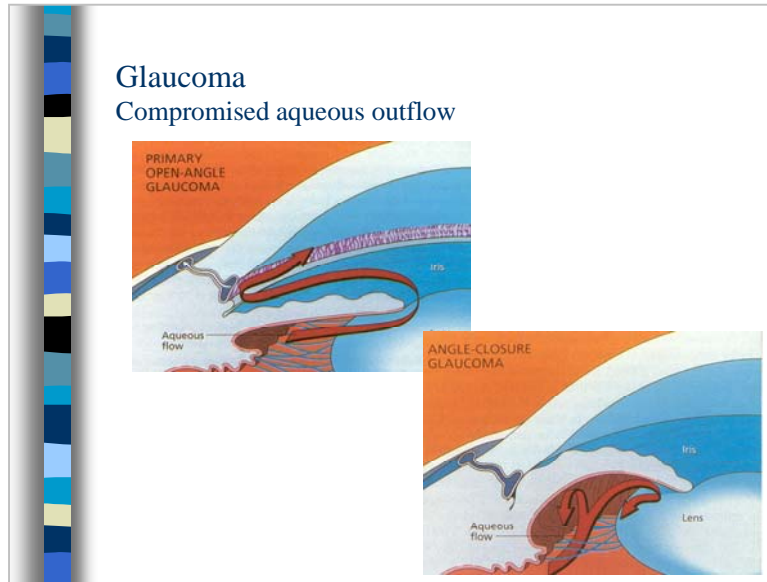

Figure 7: Schematic diagram showing compromised aqueous outflow (from Cantor *et al.*, 2000)

VI. REDUCTION OF IMAGE QUALITY BY INFLAMMATION

Inflammation is a nonspecific response by the body and represents the third level of defense against tissue compromise, *e.g.*, injury (Marieb, 2000). Inflammation can occur in the eye in many structures thereby causing a variety of inflammatory diseases (Table 9), such as, dry eyes (dry eye syndrome, or DES), keratitis, anterior uveitis, vitritis and retinitis, and optic neuritis, all of which can deteriorate retinal images and produce blurry vision.

Table 9: Inflammation	
■	DES
■	Keratitis
■	Uveitis
■	Vitritis & Retinitis
■	Optic neuritis

Dry Eye Syndrome (DES)

An appropriate air-tear interface is necessary for proper refraction of light rays (see Fig. 1 and Table 4). An unstable tear film does not refract light rays properly or uniformly and thus a clear image does not form on the retina. Systemic autoimmune disorders such as rheumatoid arthritis, lupus, and Sjogren's can result in severe DES.

Keratitis

Corneal inflammation can result from epithelial or stromal defects. Whenever the cornea is involved the patient will experience pain (from corneal nerves), photophobia (from painful dilation of iris blood vessels), and blurry vision (from edema) (Vaughan *et al.*, 2000). Edema can be epithelial or stromal, and in either case vision will be blurry because the proper spacing of cells and fibers is disrupted causing scattering of light.

Uveitis

Inflammation in the uveal tract (iris, ciliary body, and choroid), either primary or secondary to keratitis or systemic diseases, can cause an acute immune response. Anterior uveitis is the most common type of inflammation that causes pain, photophobia, and blurry vision. If inflammation is limited to the anterior chamber it is termed "iritis" whereas inflammation involving the anterior chamber and the anterior vitreous is termed "iridocyclitis" (Vaughan *et al.*, 2000). A common sign of severe iritis is "hypopyon" which is a layer of leukocytes collecting in the anterior chamber (Fig. 8A) whereas a "hyphema" is a collection of erythrocytes in the anterior chamber (Fig. 8B).

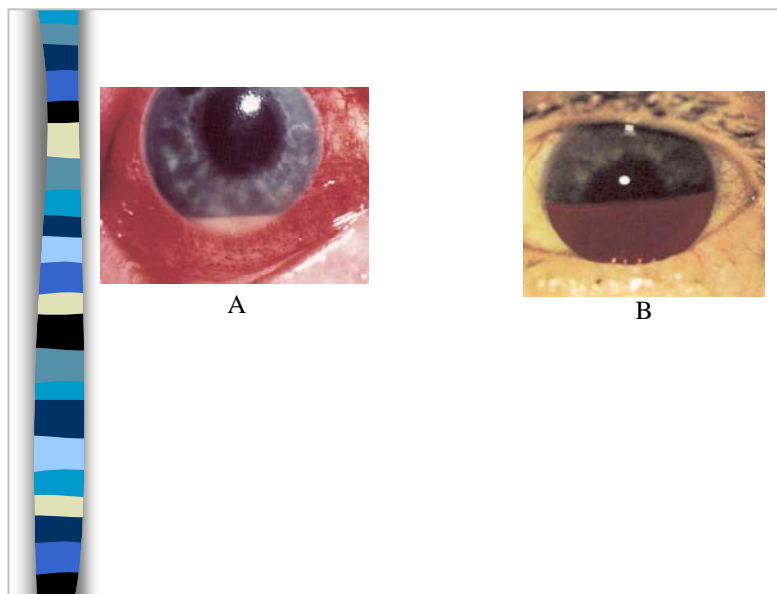


Figure 8. Examples of inflammation. (A) Hypopyon (Stein *et al.*, 2000); (B) Hyphema (Stein *et al.*, 2000)

Vitritis and Retinitis

Vitritis is inflammation of the vitreous and, along with a hypopyon, is a common sign of endophthalmitis (intraocular inflammation) which produces blurry vision (Weinberg *et al.*, 1991). Infectious organisms can gain access to the eye by the hematogenous route (endogenous endophthalmitis) or from the external environment (exogenous endophthalmitis). Vitreous haze prevents the formation of optimal images, thus resulting in symptoms of blurry vision.

Retinitis is inflammation of the retina from numerous causes, *e.g.*, *Toxoplasma gondii* an intestinal parasite in cats, *Onchocerca volvulus* a filarial parasite in sub-Saharan Africa, the fungus *Candida albicans*, *Toxocara canis* a common intestinal parasite in dogs, the fungus *Histoplasma capsulatum* which

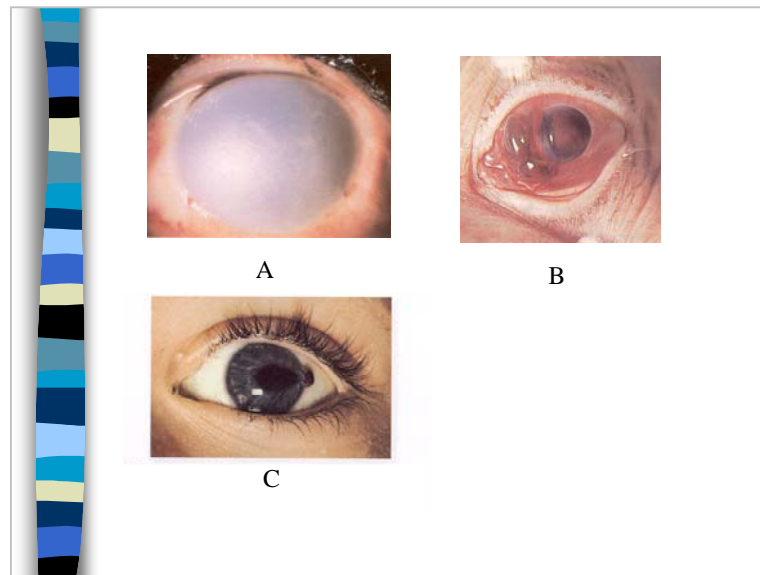


Figure 9: Examples of trauma: (A) Alkali burn (Schwab *et al.*, 1996); (B) Traumatic rupture of globe (Stamper *et al.*, 1987); (C) Penetrating injury with irregular pupil (Stein *et al.*, 2000)

Retinal Detachment

See Section 4 (Variations in Retinal Architecture)

Blowout Fracture

Orbital fractures can involve the orbit floor only (blowout fracture) or may also include the zygomatic bone (tripod fracture) (Katowitz *et al.*, 1986). In blowout fractures the inferior rectus and inferior oblique extra-ocular muscles, which support the globe, can be entrapped thus restricting eye movement in up-gaze in version testing. As with all restrictions, eye movement does not improve in duction testing (Cassin 1995). Damage to ocular tissues that refract light will result in a deterioration of images thus producing blurry vision.

Lid Laceration

Partial thickness (PTLL) or full thickness lid lacerations (FTLL) can potentially lead to serious infection if left untreated for >6 hours. Involvement of the levator can lead to ptosis, whereas involvement of the canaliculi can lead to epiphora (Stein *et al.*, 2000; Vaughan *et al.*, 2000). All these conditions will degrade the quality of images, thus affecting vision. PTLL are repaired as other skin lacerations, but FTLL are repaired by careful approximation of tissues. Failure to do so can lead to notching and trichiasis (Stein *et al.*, 2000; Vaughan *et al.*, 2000). Tightening of the notch can introduce with-the-rule astigmatism, whereas trichiasis affects the cornea. In either case the quality of images will be markedly degraded, thus producing blurry vision.

REFERENCES

1. Cantor, L, Fechtner, RD, Michael, AJ, Simmons, ST, Wilson, MR, and Brown, SVL: *Glaucoma*, Basic and Clinical Science Course, Section 10, Foundation of the American Academy of Ophthalmology, 2000, 207 p
2. Cassin, B: *Fundamentals for Ophthalmic Technical Personnel*, WB Saunders, 1995, 453 p
3. Faye, EE: Appendix 1: Visual standards, in, *General Ophthalmology*, Vaughan, D., Asbury, T., and Riordan-Eva, P., Editors, Appleton, 2000, p. 398 – 400
4. Flynn, HW, Bressler, SB, Brown, GC, Meredith, T, Regillo, CD, and Isernhagen, RD: *Retina and Vitreous*, Basic and Clinical Science Course, Section 12, Foundation of the American Academy of Ophthalmology, 2000, 367 p
5. Hardy, RA, and Crawford, JB: Retina, in, *General Ophthalmology*, Vaughan, D., Asbury, T., and Riordan-Eva, P., Editors, Appleton, 2000, p. 178 – 199
6. Katowitz, JA, Carroll, RP, Dortzbach, RK, LaPiana, FG, Sutula, FC, Vincent, NJ, Wolfley, DE, and Wulc, AE: *Orbit Eyelids, and Lacrimal System*, Basic and Clinical Science Course, Section 9, American Academy of Ophthalmology, 1986, 255 p
7. Marieb, EN, *Essentials of Human Anatomy & Physiology*, Addison, 2000, 558 p
8. O'Malley, C: Vitreous, in, *General Ophthalmology*, Vaughan, D., Asbury, T., and Riordan-Eva, P., Editors, Appleton, 2000, p. 167 - 177
9. Sanders, MD, and Graham, EM: Ocular disorders associated with systemic diseases, in, *General Ophthalmology*, Vaughan, D., Asbury, T., and Riordan-Eva, P., Editors, Appleton, 2000, p. 288 – 320
10. Schwab, IR, Epstein, RJ, Harris, DJ, Pflugfelder, SC, and Wilhelmus, KR: *External Disease and Cornea*, Basic and Clinical Science Course, Section 8, American Academy of Ophthalmology, 1996, 395 p
11. Stamper, RL, Bellows, AR, Kass, MA, Keyser, RB, Lichtenstein, SB, Stone, R: *Glaucoma, Lens, and Anterior Segment Trauma*, Basic and Clinical Science Course, Section 8, American Academy of Ophthalmology, 1987, 187 p
12. Stein HA, Slatt, BJ, Stein, RM: *The Ophthalmic Assistant*, 7th ed., Mosby, 880 p
13. Thall, EH, Miller, KM, Rosenthal, P, Schechter, RF, Steinert, RF, Beardsley, TL: *Optics, Refraction, and Contact Lenses*, Basic and Clinical Science Course, Section 3, Foundation of the American Academy of Ophthalmology, 2000, 304 p
14. Weinberg, RS, Culbertson, WW, Fischer, DH, Franklin, RM, Perry, PE, and Rao, NA: *Intraocular Inflammation and Uveitis*, Basic and Clinical Science Course, Section 9, American Academy of Ophthalmology, 1991, 175 p

LIST OF FIGURES

1. Refractive power of the air-tear-cornea interfaces
2. Optical (power) crosses for regular and irregular astigmatism
3. Diseases producing blurry images by scattering light
4. Examples of changes in retinal architecture
5. Changes in retinal architecture producing blurry images
6. Normal aqueous outflow
7. Compromised aqueous outflow
8. Examples of inflammation
9. Examples of trauma

LIST OF TABLES

1. Refractive power of ocular surfaces
2. Loss of visual function
3. Factors that reduce image sharpness
4. Reduction in image quality by variations in refraction of light
5. Reduction in image quality by scattering of light
6. Reduction in image quality by variations in retinal architecture
7. Reduction in image quality by pathology and diseases
8. Optic nerve diseases
9. Inflammation
10. Trauma

CE on the Internet Quiz

This article and accompanying quiz are worth 1 JCAHPO Group A continuing education credit.

MULTIPLE ETIOLOGIES OF BLURRY VISION

1. The role of the human eye can best be described as _____?
 - a. to form an image on the retina by imparting vergence to incoming light rays
 - b. to form an image on the retina by imparting positive vergence to incoming light rays
 - c. to form an image on the retina by imparting negative vergence to incoming light rays
 - d. to refract incoming light rays
2. Where does the principal refraction in the human eye occur?
 - a. The tear-anterior cornea interface
 - b. The posterior cornea-aqueous interface
 - c. Within the cornea
 - d. The air-tear interface
3. What is the best way to correct irregular astigmatism?
 - a. Eliminating the anterior cornea as a refractive surface
 - b. Eliminating the posterior cornea as a refractive surface
 - c. Eliminating the tears as a refractive surface
 - d. Eliminating the lens as a refractive medium
4. What is the best definition of a retinal detachment?
 - a. The separation of the retina from the vitreous
 - b. The separation of the sensory retina from the retinal pigment epithelium
 - c. The separation of the retinal pigment epithelium from the choroid
 - d. The separation of the retina and the choroid from the sclera
5. A cherry red spot in the fovea is characteristic of a retina that is ischemic because of a central retinal artery occlusion. Why is the red spot seen?
 - a. Because the retina is very thin at the fovea
 - b. Because the retina is very thin all over
 - c. Because the retina is thick all over
 - d. Because the ganglion cell layer is present all over the retina
6. What is the leading cause of preventable blindness worldwide?
 - a. Cataract
 - b. Glaucoma
 - c. Diabetic retinopathy
 - d. Trachoma
7. What is the most acceptable definition of glaucoma?
 - a. Optic nerve damage causing visual field loss
 - b. Abnormally high intraocular pressure
 - c. Abnormally low intraocular pressure
 - d. Family history of glaucoma
8. What is the most likely comparison of acid and alkali burns to the cornea?
 - a. Acid burns are self-limiting and alkali burns are also self-limiting
 - b. Acid burns are not self-limiting whereas alkali burns are self-limiting
 - c. Acid burns are self-limiting whereas alkali burns are not self-limiting
 - d. Acid burns are not self-limiting and alkali burns are also not self-limiting
9. A penetrating injury can be characterized by, among other things, one of the following signs.
 - a. Irregular pupil
 - b. Blue sclera
 - c. Steamy cornea
 - d. Loss of vision
10. A patient suspected of a blowout fracture will most likely show the following sign in the affected eye.
 - a. Pain
 - b. Possible decrease in vision
 - c. Limited up gaze
 - d. Blue sclera

CE on the Internet Answer Sheet

This article and accompanying quiz are worth 1 JCAHPO Group A continuing education credit.

You must complete the enclosed quiz on your own and may not seek assistance from other individuals in completing the quiz. You may, however, seek assistance from other individuals for clarification and understanding of the article content. Failure to comply with this policy may result in the revocation of credit.

MULTIPLE ETIOLOGIES OF BLURRY VISION

Name _____ JCAHPO Certification _____

Home Address _____

City / State / Zip _____

Home Phone _____ Work Phone _____

E-mail Address _____ Signature _____

PAYMENT INFORMATION - ALLOW 2-4 WEEKS FOR PROCESSING

Price (check one)

- ATPO Member – \$15
- ATPO Member – Complimentary*
- Non-Member – \$22
- Rush Processing - \$10.00**

**ATPO members receive 4 complimentary CE credits via CE on the Internet or COVE assessment exams.*

Method

- Check or Money Order (payable to ATPO, in U.S. funds only)
- Visa MasterCard Discover American Express

Card Number _____ Exp. Date _____

Name on Card _____ Signature _____ 3 Digit Security Code _____

Place your answers to each question in the appropriate space adjacent to the question number.

- | | |
|----------|-----------|
| 1. _____ | 6. _____ |
| 2. _____ | 7. _____ |
| 3. _____ | 8. _____ |
| 4. _____ | 9. _____ |
| 5. _____ | 10. _____ |

By filling in the above spaces and signing your name, you agree that:

- A total of 75% or more correct is a passing score.
- ATPO is not responsible for Answer Sheets and Evaluation Forms not received at the ATPO offices.

I attest that I have completed this quiz on my own. _____
(SIGNATURE)

CONTINUING EDUCATION CREDITS ARE SUBJECT TO CHANGE. Internet Articles are reviewed on a regular basis for content and amount of time needed to complete the article and quiz. We advise you to print the article and take the quiz within 30 days. Ample notice is provided when CE credits change - please check the Web site frequently for any updates and/or changes. We will accept articles for full credit within a 30-day time period when CE credits have changed or when an article has been removed from the Web site.

Return completed answer sheet,
evaluation form, and payment, to:

ATPO
Attn: CE Dept
2025 Woodlane Drive
St. Paul, MN 55125
Fax: (651) 731-0410

Questions?
Visit www.atpo.org
Call (800) 482-4858



Office Use Only	
Date Exam Received	_____
Date Exam Scored	_____
Score _____	Pass Fail
Notified Quiz Taker	_____

CE on the Internet Evaluation

MULTIPLE ETIOLOGIES OF BLURRY VISION

Please read each question carefully. Your feedback is **important** to us. Thank you!

1. How long have you been employed in the field of ophthalmology? _____ years
2. This written article was designed at a level right for me. (circle one) YES NO
3. Please read the following statements. Then, circle the number corresponding to the degree to which you agree with each statement.

Statement	Strongly Agree	Agree	Disagree	Strongly Disagree	Not Applicable
a. The material was organized and presented in a clear and efficient way.	5	4	3	2	1
b. The information will be useful/relevant to me.	5	4	3	2	1
c. The material was presented at a level appropriate to my background and level.	5	4	3	2	1
d. Overall, I was satisfied with the article.	5	4	3	2	1

4. What part of the article was **most useful** to you?

5. What part of the article was **least useful** to you?

6. What suggestions do you have for improving this article?

Thank you for completing this article evaluation! ATPO values your feedback. Please return your evaluation form with the completed quiz and payment.

Return completed answer sheet, evaluation form, and payment, to:

ATPO
Attn: CE Dept
2025 Woodlane Drive
St. Paul, MN 55125
Fax: (651) 731-0410

Questions?

Visit www.atpo.org
Call (800) 482-4858

