

Association of Technical Personnel in Ophthalmology (ATPO)

CE on the Internet Article

*This article and its accompanying quiz are worth .5 JCAHPO Group A
continuing education credit.*

CONTINUING EDUCATION CREDITS ARE SUBJECT TO CHANGE. Internet Articles are reviewed on a regular basis for content and amount of time needed to complete the article and quiz. We advise you to print the article and take the quiz within 30 days. Ample notice is provided when CE credits change - please check the Web site frequently for any updates and/or changes. We will accept articles for full credit within a 30-day time period when CE credits have changed or when an article has been removed from the Web site.

PHAKOMATOSES SYNDROMES

MICHELLE WILLIS, COMT

Objectives:

1. To familiarize ophthalmic technicians to Phakomatoses syndromes.
2. To help technicians know what type of skin, iris or eye pathology is associated with Phakomatoses syndromes and to know what questions to ask in an ophthalmic history.
3. To understand that some of the lesions or growths in Phakomatoses syndromes can become cancerous and be fatal.

PHAKOMATOSES SYNDROMES

Phakomatoses syndromes are defined as a group of multi-system syndromes that have characteristic ophthalmic manifestations. They include neurofibromatosis type I (Von Recklinghausen's disease) and type II (central neurofibromatosis), tuberous sclerosis, von Hippel-Lindau syndrome, Sturge-Weber syndrome and Wyburn-Mason syndrome. Key features may include retinal or uveal lesions. They may also have associated features of characteristic skin lesions, characteristic central nervous system lesions, and other features specific to that syndrome. There are some differences of opinion on classifying these various syndromes. Based on published research, Phakomatoses syndromes are defined as a group of independent clinical syndromes with multiple tumors or tumor-like lesions. Some of these lesions or tumors may become malignant and occur in organs of the body, and may occur in the eye in a large number of patients.

Neurofibromatosis consists of two distinct genetic diseases with considerable phenotypic overlap. These two forms are NF-1 and NF-2. Neurofibromatosis is the most common Phakomatoses syndrome, occurring 1 case per 3500 persons in the general population. NF-1 is the more common of the two affecting 1 person per 3500-4000 persons in the general population. NF-2 affects no more than 1 person per 40,000 to 50,000 persons. Men and women are affected with equal frequency and there is not a racial predilection for either type of disease. The gene for NF-1 is localized to chromosome 17q11. The gene for NF-2 has been localized to chromosome 22q12.

Neurofibromatosis type 1 (also known as peripheral NF, von Recklinhausen's disease) has certain hallmarks for classification. They include cutaneous (skin) café-au-lait spots, axillary (armpit) and inguinal (groin) freckling, Lisch nodules of the iris, several types of cutaneous neurofibromas, optic nerve gliomas, and neurofibromas or other solid neoplasms of the central nervous system (CNS).

Neurofibromatosis type 2 is known as bilateral acoustic neurofibromatosis and is rare, seen 1 in 50,000 births. People with NF-2 usually develop tumors on the nerves in their ears, causing hearing loss, eventual deafness and problems with balance.

In both types of NF, the severity of the disorder varies greatly. Both types are autosomal dominant, which means a child has a 50% chance of inheriting the disease if either parent has NF. It also can be a result of a spontaneous change (mutation) in the genetic material of the sperm or egg at conception in families with no previous history of the disease.

Statistically about half of the cases of NF are inherited, and the other half result from genetic mutation.

Many people have a few café-au-lait spots and do not have NF. If a young child has five or more of these spots, at least ¼ inch in size, a doctor will likely look for other signs of NF. These could include tumors on, under, or hanging off the skin and Lisch nodules, tiny non-cancerous tumors on the iris. Lisch nodules are of no clinical significance other than confirming a diagnosis of neurofibromatosis. A child may develop freckling in the folds of the skin of the armpit or groin or on other parts of the body where the skin creases. They may develop abnormalities of the skeleton, such as thinning or overgrowth of the bones in the arms or lower leg; curvature of the spine (scoliosis), and other bone deformities may also be features of NF-1.

NF-2 is usually seen when a child is older. Hearing loss may be seen in the late teens and early twenties. This is caused by tumors growing on the auditory nerves. Other symptoms of NF-2 might be continuous ringing of the ears, headache, facial pain or weakness, and feeling unsteady or off balance.

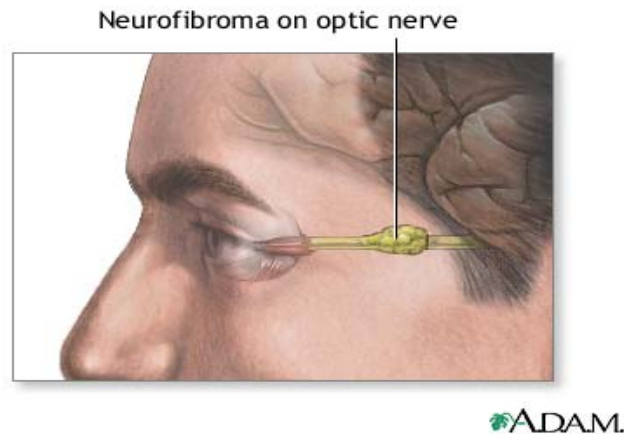
How is NF diagnosed?

A child must have at least two of the following signs to be diagnosed with NF-1.

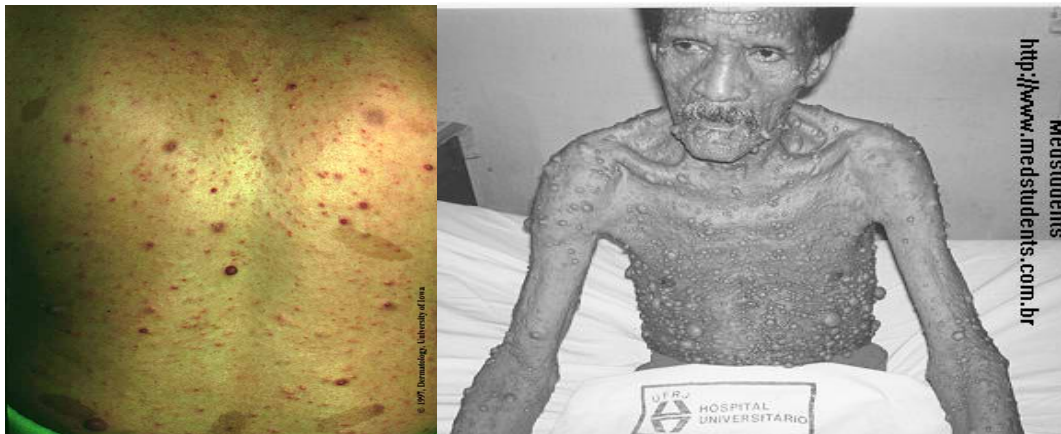- café-au-lait spots of a certain number, size, and location
- the appearance of two or more neurofibromas (pea-sized bumps on the skin)
- Lisch nodules on the irises
- optic glioma (tumor along the main nerve of the eye that is responsible for sight)
- certain skeletal abnormalities
- a family member with NF-1
- freckling under the arms or in the groin

Tests like magnetic resonance imaging (MRI) and X-rays may be used to screen for tumors or skeletal problems. A child's head circumference will be measured because children with

NF can have a larger than normal head circumference. Doctors will also take a detailed personal history.



To diagnose NF-2, the patient will be checked for any evidence of hearing loss. They will do imaging to look for tumors in the nerves of the ears, spinal cord, or brain. They'll also determine if there is a family history of NF-2.



Patients with neurofibromatosis

Genetic testing is now available for people with a family history of either NF-1 or NF-2. Amniocentesis can sometimes determine if a woman's unborn child has the condition.

Treatment of NF-1 includes removal of neurofibromas, treating the complications and getting intervention of those children with learning disabilities. Children will be referred to appropriate medical specialists to monitor their disease processes. Children with NF-1 should have physical exams and ophthalmologic evaluations. Audiology exams should be performed before the child is of school age. Children with NF-1 should be screened for scoliosis and

blood pressure should be checked at least once a year. Patients should be monitored for growth, change or pain in their neurofibromas because this could be a sign of a growth becoming malignant. Rarely, neurofibromas can become cancerous (3% to 5%). In these rare cases, surgery, chemotherapy, or radiation may be necessary. Patients with NF-2 will likely need to have their auditory nerve tumors removed, which may cause deafness afterward. In 2000 the U.S. Food and Drug Administration approved an auditory brainstem implant for people with NF-2. Currently, researchers are conducting trials with medications in the hopes they'll be able to offer more treatment options. Statistically, patients with NF-1 have an estimated 3-15% additional risk of malignant disease in their lifetime.

TUBEROUS SCLEROSIS

Also known as TSC or TS, this is a rare genetic disease that causes benign tumors to grow in the brain and other vital organs such as the eyes, kidneys, heart, lungs and skin. It can affect the central nervous system (CNS). There are three types of brain tumors that are associated with TS. They are cortical tubers, subependymal nodules, and giant-cell astrocytomas. Statistically there is approximately 1 case per 10,000 people in the general population group. About one third of cases are familial and two thirds are sporadic. No racial predilection exists and the sexes are affected equally. Signs and symptoms of TS usually begin by the time the patient is age six. TS genes have been identified on loci on the long arm of chromosome 9 (9q32-34), on the long arm of chromosome 11, on the short arm of chromosome 16(16p13), and on the long arm of chromosome 12 (12q22-24). Of the loci, the 9q32-34 locus has been the most consistent and is associated with one third to one half of all familial cases.

What are the treatments? There are no known cures for TS. Antiepileptic drugs may be used to control seizures and medications can be used to control behavior problems. Intervention programs are utilized for those individuals requiring special schooling and occupational therapy. Surgery including dermabrasion and laser treatment may be used to treat skin lesions. TS is a lifelong condition and individuals will need to be monitored for life.

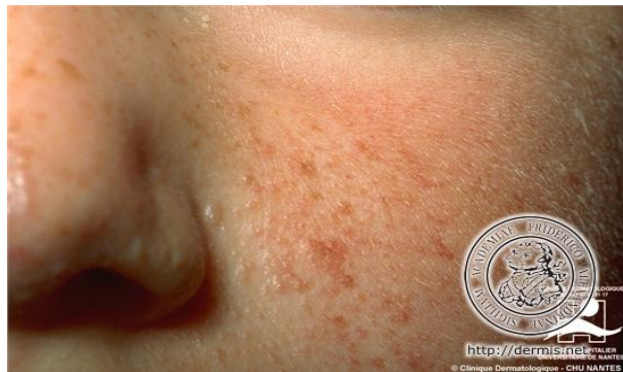There are many other findings that can occur in TS. Central nervous system tumors can occur and are usually low-grade astrocytomas. Complications associated with such lesions can include mental deficiency and seizures. Many individuals who have TS have normal intellectual abilities. The cutaneous lesions most commonly associated with TS include

adenoma sebaceum, ash leaf spots, shagreen patches, and subungual fibromas. Adenoma sebaceum is a skin eruption that is classified as pinhead to pea-sized yellowish to reddish-brown papules on the face in a butterfly like pattern over the nose, cheeks, and nasolabial folds. The shagreen patch is a thicker area of skin that has the texture of pigskin or sharkskin and usually occurs over the lower back. Other unusual tumors can develop in the heart, kidneys, lungs, thyroid, and other visceral organs. The most common visceral tumor is the angiomyolipoma of the kidney. These patients are also at risk of developing benign cardiac rhabdomyoma and an unusual lung disease called pulmonary lymphangiomyomatosis. Cysts can also develop in all these various organs.

The classic eye feature of TS is the retinal astrocytoma. About 50% of all TS patients develop at least one retinal astrocytoma in one eye. These tumors can become malignant, although this is rare. Systemic evaluations for these patients should include fundus examination, dermatological evaluation, CT or MRI of the central nervous system, and CT or MRI of the abdominal area. Family members should be evaluated as well, to look for a familial pattern.

The life expectancy of TS patients is reduced substantially compared to the normal population. The most common cause of early death is renal failure. The second most common cause is obstructive hydrocephalus or other CNS problems. Less frequent causes of death are cardiac conduction defects and heart failure.

Adenoma sebaceum of the face seen with tuberous sclerosis



VON HIPPEL-LINDAU SYNDROME

VHLS is a multi-organ problem, which is characterized by retinal capillary hemangiomas, CNS hemangioblastomas, solid and cystic visceral hamartomas and hamartias, and malignant neoplasms that can include renal cell carcinomas. This syndrome can run in families and has a clear autosomal dominant inheritance pattern. Individuals run the risk of early death, usually secondary to intracranial hemangiomatous lesions or renal cell carcinoma.

VHLS is very rare and its precise incidence has not been established. The signs of this disease are usually seen before the third decade of life. The median age at detection is usually between ages 20 and 25 years of age. The probability of developing retinal capillary hemangiomas and CNS hemangioblastomas in a patient who has VHLS is >80% and the probability of developing renal cell carcinoma is > 60 %.

VHLS affects both men and females equally and occurs in all racial groups. The VHLS gene has been identified to Chromosome 3p25-26.

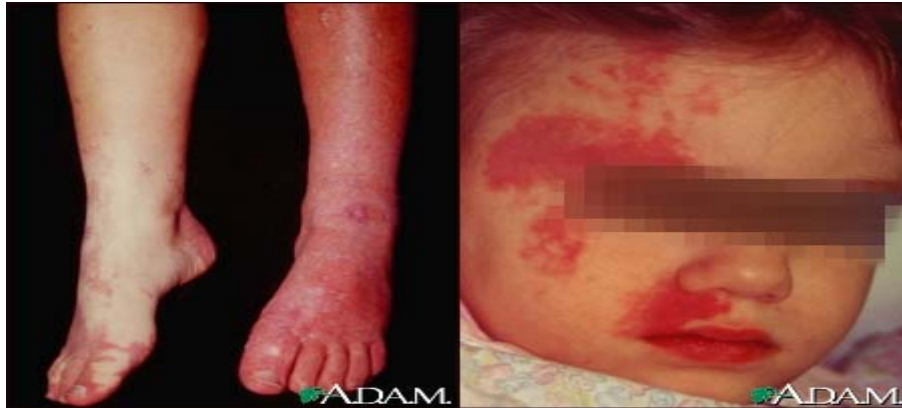Renal cell tumors can metastasize, so it must be recognized early and treated aggressively to avoid a fatal outcome. VHLS patients can also have visceral neoplasms, islet cell carcinoma of the pancreas and cyst –adenomas of the pancreas and epididymis. Also, VHLS patients can develop multifocal cysts in many organs. VHLS patients do not have dermatological lesions as part of this syndrome. First and second-degree relatives are at risk for VHLS. The only way to determine with certainty if a patient has VHLS is with DNA testing.

STURGE-WEBER SYNDROME

SWS is a rare congenital syndrome that can consist of a port wine stain (benign blood vessel tumor) on the face and sometimes other parts of the body, ipsilateral meningeal hemangiomatosis and ipsilateral diffuse cavernous hemangioma of the choroid. The lesions can occur in the eye, skin, and brain, and are present at birth. There have only been a few familial clusters of this syndrome reported and of those, none have exhibited a clear-cut autosomal dominant inheritance pattern seen with NF, TS, and VHLS.

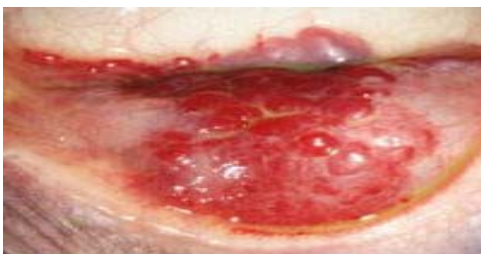The incidence of SWS is approximately one per 50,000 live births in the United States. No gender differences have been noted. Only about 13% of SWS cases present without the port wine stain. Also, some children with the port wine stain will not have Sturge-Weber Syndrome. The exact cause and incidence of SWS is not known. Weakness of one side of the body (hemiparesis) can be treated with physical and occupational therapy.

Port wine stains of leg and face




A child born with this syndrome has a higher likelihood of the following clinical signs:

- port wine stain: 8-15 %
- bilateral brain involvement: 15%
- choroidal hemangioma (nonmalignant blood vessel tumors in the eye) 40%
- glaucoma 30-71%
- seizure: 72-93%
- hemiparesis (weakness on one side of the body): 25-56 %
- hemianopsia (loss of half of the field of vision): 44%
- headaches: 44-62%
- developmental delay/ mental retardation; 50-75%



Strawberry hemangioma of lower eyelid



Visual field demonstrating hemianopsia

Healthcare staff will immediately evaluate a baby born with a port wine stain. In some instances a port wine stain will not be present and these cases usually do not get detected until the child has a seizure or other neurological problem. If neurological involvement is suspected these tests may be ordered:

- X-ray of the skull to show calcifications
- CT scan of skull to show calcifications, abnormal veins, and brain atrophy
- MRI to show angiomas
- Computed tomography to measure blood flow in the brain
- EEG to evaluate seizures

Treatment for this syndrome depends on the disorders involved. Port wine stains can be treated with laser treatment to help remove or lighten the stain. Multiple treatments are usually necessary. Seizure activity is usually treated with drug therapy. In this particular syndrome, seizures are often resistant to treatment. Early surgical removal of the part of the brain with the abnormal blood vessels may be considered in some cases. Drug therapy may be used to treat glaucoma. PDT (photodynamic therapy) may be used to treat choroidal hemangiomas that affect the eye. Medications may be used to treat migraines. A wide range of treatment options is available for those children with developmental delays or learning problems.

This is not a fatal disease. The long-term outlook depends on the specific neurological problems present. Successful treatment of seizures can improve the outlook for children with SWS.

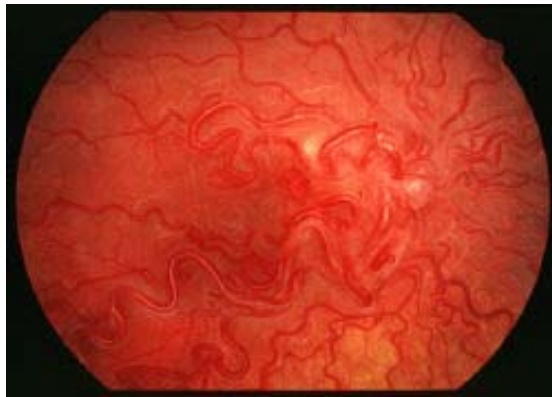
WYBURN-MASON SYNDROME

WMS has arteriovenous malformations (AVMs) of the retina and ipsilateral CNS. These lesions are not distinct tumors but classified as anomalous arteriovenous vessels. Most patients have unilateral nonfamilial disease. A familial pattern has not been identified.

This syndrome is very uncommon and the retinal and intracranial vessels of WMS are congenital. These arteriovessel anomalies are usually not completely developed at birth. They progress during the aging process. Most patients present with retinal and CNS

malformations in the second through the fourth decades of life. Men and women are equally affected. No racial predilection occurs and no hereditary pattern has been identified.

Arteriovenous malformations can occur in the orbit, in the periorbital soft tissues and bones, and in the midbrain ipsilateral to the retinal AVM. Only the patients who have CNS AVMs and retinal AVMs should be considered to have WMS. Usually, the more complex the arteriovenous malformation, the higher incidence of CNS AVMs.



Retinal arteriovenous malformations

The classic hallmark of WMS is the AVM of the retina. Evaluation of a patient who has retinal AVMs, usually include an MRI and possibly MRA of the orbit and brain.

Treatment for complex intracranial AVMs can sometimes be intracranial resection, arterial ligation, arterial embolization, stereotactic radiosurgery, or charged particle beam irradiation.

These patients usually have a shortened life span due to early deaths secondary to spontaneous bleeding from the intracranial arteriovenous malformations and strokes related to their treatment. Also, the affected eye may become blind secondary to spontaneous or post occlusion treatment of the retinal AVM.

WHY IS IT IMPORTANT FROM AN OPHTHALMIC TECHNICIAN STANDPOINT TO KNOW IF A PATIENT IS REFERRED FOR ONE OF THESE POSSIBLE SYNDROMES?

Many of the patients may have a skin pigmentary pattern, iris nodules, retinal lesions, hemangiomas, possible glaucoma, but more importantly, some of these syndromes can be

associated with other multi-organ lesions which can be fatal if not treated aggressively. Recognizing a particular syndrome and referring a patient for further screening in regard to a specific syndrome might well prolong a patient's life expectancy. While it is not the technicians' job to refer to other specialists, it is our job to include a thorough history. Knowing what findings correlate with specific syndromes may help us to ask more specific questions with our historical data collection. It may also help the technician to route the patient accordingly through the clinic. One example might be the patient who has possible neurofibromatosis and is referred for an eye evaluation. We need to ensure the patients get a very thorough iris evaluation to check for Lisch nodules prior to dilation of their pupils. When we take an appropriate history and help route the patients appropriately, the physician can then further ensure that other referrals and evaluations are scheduled as appropriate.

References

1. Yanoff M, Duker J S. Ophthalmology. Second Edition. Mosby, Missouri. 2004.
2. http://ninds.nih.gov/disorders/tuberous_sclerosis/tuberous_sclerosis.htm
3. <http://www.medstudents.com.br/neuro/neuro7.htm>
4. <http://www.emedicine.com/DERM/topic287.htm>
5. <http://www.answers.com/topi/sturge-weber-syndrome>

PHAKOMATOSES SYNDROMES

This article and accompanying quiz are worth .5 JCAHPO Group A continuing education credit.

1. Which condition below does not belong in the group labeled Phakomatoses Syndromes?
 - a. Neurofibromatosis
 - b. Sturge-Weber Syndrome
 - c. Tuberous Sclerosis
 - d. Sarcoidosis

2. A Lisch nodule is a small spot or spots on the iris associated with what specific condition?
 - a. Sturge –Weber Syndrome
 - b. Tuberous Sclerosis
 - c. Neurofibromatosis
 - d. Wyburn Mason Syndrome

3. The classic hallmark of Wyburn Mason Syndrome is:
 - a. Port wine stain
 - b. Retinal arteriovenous malformation
 - c. Café au lait spots on skin
 - d. Associated glaucoma

4. Of the Phakomatoses syndromes, which condition is the most common?
 - a. Tuberous Sclerosis
 - b. Neurofibromatosis
 - c. Sturge-Weber Syndrome
 - d. Von Hippel- Lindau Syndrome
 - e. Wyburn Mason Syndrome

5. Which finding is not found with Neurofibromatosis?
 - a. Retinal hemangioma
 - b. Lisch nodules
 - c. Freckling under the arms or groin
 - d. Pea-sized bumps on the skin
 - e. Café au-lait spots on the skin

6. The median age of detection for Von Hippel-Lindau Syndrome is:
- 50 to 55 yrs. of age
 - 10 to 15 yrs. of age
 - 20 to 25 yrs. of age
 - At birth or congenital
7. Of the Sturge-Weber Syndrome cases only about _____ % of the cases do not have a port wine stain.
- 13%
 - 1%
 - 5%
 - 20%
8. One of the main reasons children with Sturge-Weber Syndrome are referred to an ophthalmologist is to rule out _____.
- Cataract
 - Esotropia
 - Glaucoma
 - Retinal detachment
9. A child born with Sturge-Weber Syndrome has a _____% incidence of seizures.
- 12% to 23%
 - 25% to 35%
 - 72% to 93%
 - 95% to 100%
10. Port wine stains may be removed with multiple treatments of
- Laser
 - PDT treatments
 - Dermabrasion
 - A skin bleaching process

Internet Answer Sheet

This article and accompanying quiz are worth .5 JCAHPO Group A continuing education credit.

You must complete the enclosed quiz on your own and may not seek assistance from other individuals in completing the quiz. You may, however, seek assistance from other individuals for clarification and understanding of the article content. Failure to comply with this policy may result in the revocation of credit.

PHAKOMATOSES SYNDROMES

Name _____ JCAHPO Certification _____

Home Address _____

City / State / Zip _____

Home Phone _____ Work Phone _____

E-mail Address _____ Signature _____

PAYMENT INFORMATION - ALLOW 2-4 WEEKS FOR PROCESSING Price (check one)

ATPO Member – \$8

ATPO Member – Complimentary*

Non-Member – \$12

Rush Processing - \$10.00

***ATPO members receive 4 complimentary CE credits via CE on the Internet or COVE assessment exams.**

Method of Payment: Check (payable to ATPO) VISA MasterCard Discover Am. Express

Credit Card #: _____

Expiration Date: _____ Security (SVC) Code (on back of credit card): _____

Name of Cardholder (please print): _____

Cardholder's billing address: _____

Cardholder's Signature: _____

Place your answers to each question in the appropriate space adjacent to the question number.

1. _____
2. _____
3. _____
4. _____
5. _____

6. _____
7. _____
8. _____
9. _____
10. _____

By filling in the above spaces and signing your name, you agree that:

- A total of 75% or more correct is a passing score.
- ATPO is not responsible for Answer Sheets and Evaluation Forms not received at the ATPO offices.

I attest that I have completed this quiz on my own.

(SIGNATURE)

CONTINUING EDUCATION CREDITS ARE SUBJECT TO CHANGE. Internet Articles are reviewed on a regular basis for content and amount of time needed to complete the article and quiz. We advise you to print the article and take the quiz within 30 days. Ample notice is provided when CE credits change - please check the Web site frequently for any updates and/or changes. We will accept articles for full credit within a 30-day time period when CE credits have changed or when an article has been removed from the Web site.

**Return completed answer sheet,
evaluation form, and payment to:**

ATPO
Attn: CE Dept
2025 Woodlane Drive
St. Paul, MN 55125
Fax: (651) 731-0410

Questions?
Visit www.atpo.org
Call (800) 482-4858



Office Use Only

Date Exam Received _____

Date Exam Scored _____

Score _____ Pass Fail

Notified Quiz Taker _____

CE on the Internet Evaluation

PHAKOMATOSES SYNDROMES

Please read each question carefully. Your feedback is important to us. Thank you!

- 1. How long have you been employed in the field of ophthalmology? _____ years
2. This written article was designed at a level right for me. (circle one) YES NO
3. Please read the following statements. Then, circle the number corresponding to the degree to which you agree with each statement.

Table with 6 columns: Statement, Strongly Agree, Agree, Disagree, Strongly Disagree, Not Applicable. Rows include statements about material organization, usefulness, and satisfaction.

4. What part of the article was most useful to you?

Two horizontal lines for writing the answer to question 4.

5. What part of the article was least useful to you?

Two horizontal lines for writing the answer to question 5.

6. What suggestions do you have for improving this article?

Two horizontal lines for writing the answer to question 6.

Thank you for completing this article evaluation! ATPO values your feedback. Please return your evaluation form with the completed quiz and payment.

ATPO
Attn: CE Dept
2025 Woodlane Drive
St. Paul, MN 55125
Fax: (651) 731-0410

Questions?
Visit www.atpo.org
Call (800) 482-4858

