

Association of Technical Personnel in Ophthalmology (ATPO)

CE on the Internet Article

This article and accompanying quiz are worth .5 JCAHPO Group A continuing education credit.

CONTINUING EDUCATION CREDITS ARE SUBJECT TO CHANGE. Internet Articles are reviewed on a regular basis for content and amount of time needed to complete the article and quiz. We advise you to print the article and take the quiz within 30 days. Ample notice is provided when CE credits change - please check the Web site frequently for any updates and/or changes. We will accept articles for full credit within a 30-day time period when CE credits have changed or when an article has been removed from the Web site.

POSTERIOR VITREOUS DETACHMENT AND ITS SEQUELAE

Michael W. Stewart, M.D.

Introduction

The vitreous is the largest tissue in the human eye and is responsible for numerous ophthalmologic diseases. Its pre-programmed degeneration from early childhood through adult life leads to vitreous detachment and subsequent retinal problems, many of which are sight threatening. This article discusses the vitreous anatomy, its subsequent degeneration leading to detachment and its sequelae such as retinal tears, retinal detachments and macular puckers.

Objectives

After reading this article the student should:

1. Be familiar with the 3 embryological stages of vitreous development.
2. Understand the degenerative changes leading to vitreous detachment.
3. Recognize the typical symptoms and signs of posterior vitreous detachment.
4. Be familiar with the more common sequelae of vitreous detachment.

The vitreous is the largest single tissue of the human eye with an average volume of 5 ml. Though many people view the vitreous as a relatively inert and optically empty substance, it causes many ocular problems and is secondarily affected by several retinal and choroidal disorders. The most common pathological vitreous condition is the posterior vitreous detachment. In this article I will discuss the vitreous anatomy, its natural degeneration leading to vitreous detachment, and the sequelae to this.

During embryological development the vitreous forms in 3 stages: the primary, secondary and tertiary vitreous. The primary vitreous, which forms during the first trimester of life, consists of primitive fetal vasculature emanating from the optic nerve head. It grows anteriorly to the developing crystalline lens, enveloping it with the tunica vasculosa lentis. This nourishes the lens during its development and also produces the secondary vitreous, which comprises the majority of the adult eye's posterior segment volume. The primary vitreous then involutes, though remnants such as a Burgmeister papilla and Cloquet's canal may persist. In severe cases, extensive scar tissue contiguous with the optic disc and/or posterior lens capsule, called persistent fetal vasculature (previously known as PHPV or persistent hyperplastic primary vitreous), remains. The tertiary vitreous, comprising the vitreous base and the cortical vitreous, accounts for the strong vitreous adhesion to the pars plana and forms the interface with the retina and posterior lens capsule.

Fully formed vitreous has the consistency of soft gelatin. The inherent difficulty in histologically preserving and analyzing gels has challenged anatomists attempting to identify a definite vitreous structure. However, most experts now agree that the vitreous arrangement consists of an "onion peel" configuration surrounding a central "orange slice" arrangement¹. Throughout these partitions run microscopic channels through which liquid vitreous percolates. Though gel-like in consistency, the vitreous is 99% water with several dissolved salts, thus giving the liquid a chemical composition similar to normal saline. Collagen fibrils, with chemically bound sodium hyaluronate molecules, traverse the gel in regular patterns.

Though we know that the gel-like consistency is due to collagen-hyaluronate bonding, the evolutionary reason for this composition is unknown. Three theories have been advanced to explain this. The vitreous may act as a "shock absorber" to prevent dislocation of internal structures such as the lens and iris during severe blunt trauma. Secondly, the high viscosity of the vitreous may prevent excessive anteroposterior movements of the lens-iris diaphragm, thereby stabilizing the eye and maintaining a more accurate focusing ability at all times. Finally, some fish have vitreous both in front of and behind the crystalline lens to dampen accommodative movements. The vitreous may therefore suppress an over/under accommodative movement and allow the eye to acquire the correct accommodative configuration in the shortest possible time.

The vitreous composition at birth is entirely gel-like, but it begins to naturally degenerate at 5 years of age. The sodium hyaluronate molecules dissociate from the collagen fibrils causing them to condense into larger collagen fibers. This creates pockets of liquid vitreous in which there exist only saline and hyaluronate but no collagen fibers. The formation of these liquid-only spaces is called vitreous syneresis. Progressive syneresis eventually leads to collapse of the vitreous macrostructure with detachment of the posterior cortical vitreous from the surface of the retina. To fill in the newly created space between the posterior hyaloid membrane and the retina requires a hole in the surface of the hyaloid to allow liquid vitreous to pass into the pre-retinal space. This natural defect exists in the form of the regressed primary vitreous tract overlying the optic nerve head. Following the detachment of the posterior hyaloid, the dense ring of collagen surrounding this hole – known as a Weiss ring - becomes visible in the mid-vitreous cavity. Due to the shadow formed by this dense tissue, patients will often complain of seeing a circular or curved floater; they may describe this as a web, bug or gnat. In some patients the vitreous collapse with its redundancy and folding of the posterior hyaloid causes patients to describe a "film" over the eye.

Small, pinpoint spots in the vision are a common complaint following an uncomplicated vitreous detachment. However, a patient complaining of dozens or hundreds of tiny specks has more likely experienced a vitreous hemorrhage or a retinal tear. The hemorrhage may be due to shearing and tearing of a peripheral, superficial retinal vessel, the stretching of an avulsed retinal vessel (Fig. 1) or, most commonly, bisection of a blood vessel at the site of a retinal tear. A general rule is that a vitreous detachment with associated vitreous hemorrhage has a retinal tear until proven otherwise.

Retinal tears allow the liberation of retinal pigment epithelial cells into the vitreous (Schaeffer's sign) which often can be seen just behind the lens with slit lamp biomicroscopy. A positive Schaeffer's sign is nearly always associated with a retinal tear.

Patients developing vitreous detachments frequently complain of flashing lights (photopsias). These are caused by intermittent vitreous traction on the retina with mechanical stimulation of the photoreceptors, and the subsequent interpretation by the brain as light flashes. These usually appear early in the course of a PVD and are generally gone within a few weeks. Some patients experience light flashes associated with eye or head movement that persist months and years after the initial vitreous detachment. These are probably due to the residual vitreous gel intermittently striking the retina, causing stimulation through pressure. Flashes of this type are generally benign.

Posterior vitreous detachments spontaneously occur with increasing frequency past the age of 45 years. Throughout the population, 53% of patients past the age of 50 and 65% of patients past the age of 65 have vitreous detachments. PVD is more frequently seen in women than in men suggesting that vitreous degeneration is under some hormonal regulation. Detachments may occur at any age following blunt or penetrating trauma, ocular inflammation, hemorrhage, or intraocular surgery such as cataract extraction.

More than 90% of vitreous detachments cause no long-term vision-threatening sequelae. However, some patients develop horseshoe retinal tears due to persistent vitreoretinal traction. Recently formed horseshoe retinal tears with associated flashes and floaters have a 50% chance of causing a retinal detachment. Urgent treatment of these tears with either cryoretinopexy or laser retinopexy is indicated. Both of these modalities surround the tear with chorioretinal scars, leading to a strong adhesion between the retina and underlying choroid. With appropriate case selection and meticulous surgical technique each of these treatments is 96% successful in preventing retinal detachments. The selection of laser or cryo depends upon the location of the tear, the presence of overlying vitreous hemorrhage, cataract, the amount of surrounding subretinal fluid and the preference of the surgeon. Some horseshoe tears are followed by spontaneous avulsion of the retinal flap. Retinopexy is usually not required for these operculated retinal holes since vitreoretinal traction is no longer present.

Continued, unopposed vitreoretinal traction allows liquid vitreous to pass through the retinal defect and dissect the neurosensory retina from the underlying pigment epithelium. This separation is called a rhegmatogenous (hole-related) retinal detachment to differentiate it from traction retinal detachment or exudative retinal detachments. Some asymptomatic, inferior, peripheral rhegmatogenous retinal detachments may be observed. However, most retinal detachments carry a high risk of rapid progression to total visual loss and, therefore, require surgical treatment. The most common surgical approach is scleral buckling which has an 80-90% single surgery success rate. Many superior detachments can be successfully fixed with pneumatic retinopexy (combined intravitreal gas injection and cryoretinopexy). Some surgeons use vitrectomy as their primary surgical treatment for detachments.

Blunt ocular trauma is a common cause of several types of retinal breaks. The anteroposterior shortening of the globe with secondary equatorial expansion causes significant stretching of the vitreous base. This results in horseshoe retinal tears, giant retinal tears (tears of at least 90 degrees of the retina's circumference) and retinal dialyses (disinsertion of the retina from the ora serrata). If left untreated, these lesions frequently progress to retinal detachments. Giant retinal tears are particularly challenging to repair since the torn retina often folds upon itself like a taco. Surgical treatment consists of vitrectomy with the intraoperative use of heavy perfluorocarbon liquids to unfold the retina.

Thin sheets of scar tissue may grow on the surface of the macula following some vitreous detachments. The scar's high collagen content causes contraction of the membrane, leading to wrinkling or "puckering" of the underlying retina (Fig. 2). This epiretinal membrane may cause varying degrees of visual distortion and loss of acuity. For symptomatic patients with decreased vision, vitrectomy surgery with stripping of the epiretinal membrane provides an 85% chance of improved vision.

Posterior vitreous detachments do not always become complete as the tenacious vitreous attachments to the macula and optic nerve sometimes do not release. Eyes with this persistent vitreopapillary and vitreomacular traction develop optic nerve swelling and shallow traction macular detachments.

Visual acuity is often diminished to the 20/50 to 20/100 level. Vitrectomy and membrane stripping surgery with release of the vitreous traction results in improved vision but these eyes are usually plagued with persistent visual deficits.

Patients who call with new flashes and floaters should be examined within a couple of days. Though more than 90% of patients with posterior vitreous detachments have benign outcomes approximately 1 in 10,000 people in the general population will develop retinal detachments each year. Many of these can be prevented with timely evaluation and preventative treatment.

Figure 1. (*photo 6065_3*)

The avulsed retinal arteriole between the dark lines is elevated from the retina by the detached vitreous.

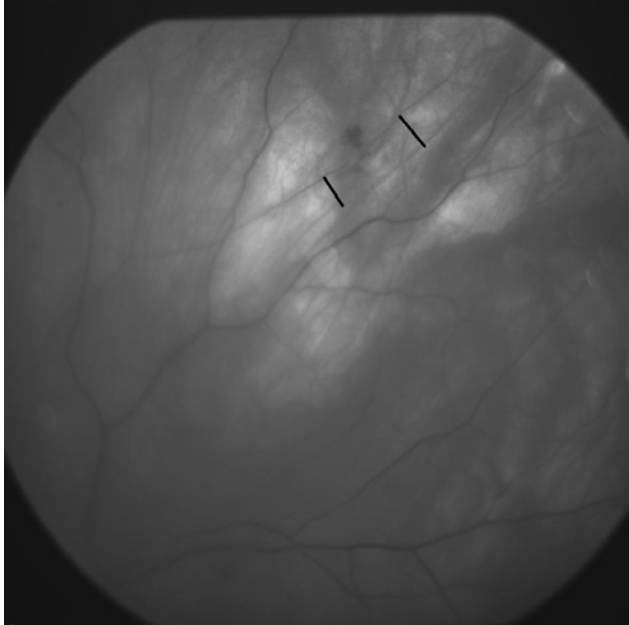
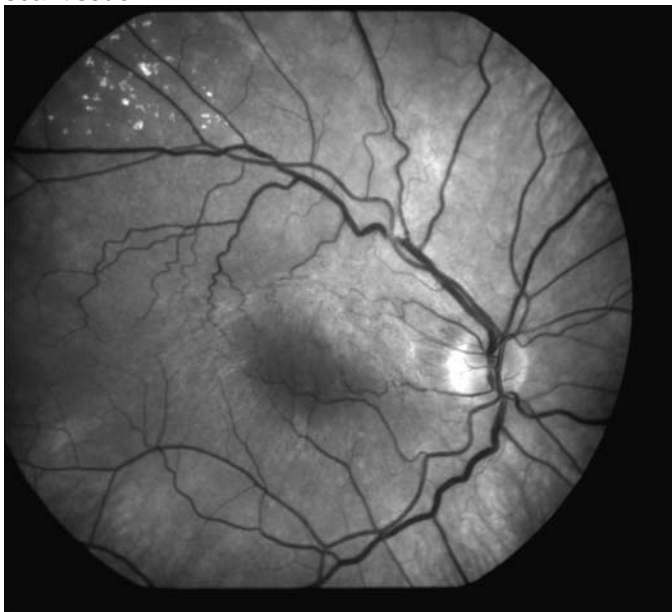

Figure 2. (*photo 10690_1*)

Notice the superiorly dislocated macula, the tortuous, small retinal vessels and the faint, white epiretinal scar tissue.



Summary

Posterior vitreous detachment represents the culmination of an ocular degenerative process that begins shortly after birth. Most affected patients are temporarily troubled by flashes and floaters though their vision is ultimately unaffected. However, the potential development of severe sequelae such as retinal tear, retinal detachment, macular pucker, avulsed retinal vessel and vitreomacular traction mandate a timely, thorough eye examination to ensure the best outcome.

References

1. Eisner G. "Clinical Anatomy of the Vitreous" in Foundations of Clinical Ophthalmology. Lippincott, Philadelphia. 1992.
2. Balazs EA, Flood MT. Age-related changes in the physical and chemical structure of human vitreous [abstr]. Third International Congress of Eye Research, Osaka, Japan 1978.
3. Lindner B. Acute posterior vitreous detachment and its retinal complications. Acta Ophthalmol (suppl) 1966;87:1.

CE on the Internet Quiz

This article and accompanying quiz are worth .5 JCAHPO Group A continuing education credit.

POSTERIOR VITREOUS DETACHMENT AND ITS SEQUELAE

1. The vitreous forms in how many different stages?
 - a. 1
 - b. 2
 - c. 3
 - d. 4

2. The typical ring-like floater associated with a posterior vitreous detachment is called a
 - a. Cloquet's canal
 - b. Weiss ring
 - c. Bergmeister papilla
 - d. Persistent fetal vasculature

3. Which of the following are typical symptoms of a vitreous detachment?
 - a. Flashes of light
 - b. A "web-like" floater
 - c. Multiple small spots in the vision
 - d. All of the above

4. The success rate for treating a retinal tear with cryoretinopexy or laser is
 - a. 20%
 - b. 44%
 - c. 76%
 - d. 96%

5. Perfluorocarbon liquids are frequently used to treat
 - a. Horseshoe retinal tears
 - b. Giant retinal tears
 - c. Macular puckers
 - d. Vitreomacular traction syndromes

6. Which of the following is the major component of the vitreous?
 - a. Salt water
 - b. Fibrils
 - c. Sodium hyaluronate
 - d. Cells

7. Which of the following first approaches may be used to treat a retinal detachment?
 - a. Pneumatic retinopexy
 - b. Scleral buckle
 - c. Vitrectomy
 - d. All of the above

8. Normal vitreous degeneration begins at what age?
 - a. Birth
 - b. 5 years
 - c. 50 years
 - d. 65 years

9. Which of the following evolutionary theories has been put forth to explain the gel-like consistency of the vitreous?
 - a. Acts as a shock absorber to minimize the effects of trauma
 - b. Prevents excessive anterior-posterior movement of the lens/iris diaphragm
 - c. Prevents over/under accommodation by the lens
 - d. All of the above

10. Which of the following does not usually require treatment?
 - a. Horseshoe retinal tear
 - b. Retinal dialysis
 - c. Giant retinal tear
 - d. Operculated retinal hole

CE on the Internet Answer Sheet

This article and accompanying quiz are worth .5 JCAHPO Group A continuing education credit.

You must complete the enclosed quiz on your own and may not seek assistance from other individuals in completing the quiz. You may, however, seek assistance from other individuals for clarification and understanding of the article content. Failure to comply with this policy may result in the revocation of credit.

POSTERIOR VITREOUS DETACHMENT AND ITS SEQUELAE

Name _____ JCAHPO Certification _____

Home Address _____

City / State / Zip _____

Home Phone _____ Work Phone _____

E-mail Address _____ Signature _____

PAYMENT INFORMATION - ALLOW 2-4 WEEKS FOR PROCESSING

Price (*check one*)

- ATPO Member – \$8
- ATPO Member – Complimentary*
- Non-Member – \$12
- Rush Processing - \$10.00

**ATPO members receive 4 complimentary CE credits via CE on the Internet or COVE assessment exams.*

Method

Method of Payment: Check (payable to ATPO) VISA MasterCard Discover Am. Express

Credit Card #: _____

Expiration Date: _____ Security (SVC) Code (on back of credit card): _____

Name of Cardholder (please print): _____

Cardholder's billing address: _____

Cardholder's Signature: _____

Place your answers to each question in the appropriate space adjacent to the question number.

- | | |
|----------|-----------|
| 1. _____ | 6. _____ |
| 2. _____ | 7. _____ |
| 3. _____ | 8. _____ |
| 4. _____ | 9. _____ |
| 5. _____ | 10. _____ |

By filling in the above spaces and signing your name, you agree that:

- A total of 75% or more correct is a passing score.
- ATPO is not responsible for Answer Sheets and Evaluation Forms not received at the ATPO offices.

I attest that I have completed this quiz on my own. _____

(SIGNATURE)

CONTINUING EDUCATION CREDITS ARE SUBJECT TO CHANGE. Internet Articles are reviewed on a regular basis for content and amount of time needed to complete the article and quiz. We advise you to print the article and take the quiz within 30 days. Ample notice is provided when CE credits change - please check the Web site frequently for any updates and/or changes. We will accept articles for full credit within a 30-day time period when CE credits have changed or when an article has been removed from the Web site.

Return completed answer sheet,
evaluation form, and payment, to:

ATPO
Attn: CE Dept
2025 Woodlane Drive
St. Paul, MN 55125
Fax: (651) 731-0410

Questions?
Visit www.atpo.org
Call (800) 482-4858



| Office Use Only | | |
|---------------------|-------|------|
| Date Exam Received | _____ | |
| Date Exam Scored | _____ | |
| Score | Pass | Fail |
| Notified Quiz Taker | _____ | |

CE on the Internet Evaluation

POSTERIOR VITREOUS DETACHMENT AND ITS SEQUELAE

Please read each question carefully. Your feedback is **important** to us. Thank you!

1. How long have you been employed in the field of ophthalmology? _____ years
2. This written article was designed at a level right for me. (circle one) YES NO
3. Please read the following statements. Then, circle the number corresponding to the degree to which you agree with each statement.

| Statement | Strongly Agree | Agree | Disagree | Strongly Disagree | Not Applicable |
|--|----------------|-------|----------|-------------------|----------------|
| 1. The material was organized and presented in a clear and efficient way. | 5 | 4 | 3 | 2 | 1 |
| 2. The information will be useful/relevant to me. | 5 | 4 | 3 | 2 | 1 |
| 3. The material was presented at a level appropriate to my background and level. | 5 | 4 | 3 | 2 | 1 |
| 4. Overall, I was satisfied with the article. | 5 | 4 | 3 | 2 | 1 |

4. What part of the article was **most useful** to you?

5. What part of the article was **least useful** to you?

6. What suggestions do you have for improving this article?

Thank you for completing this article evaluation! ATPO values your feedback. Please return your evaluation form with the completed quiz and payment.

Return completed answer sheet, evaluation form, and payment, to:
 ATPO
 Attn: CE Dept
 2025 Woodlane Drive
 St. Paul, MN 55125
 Fax: (651) 731-0410

Questions?
 Visit www.atpo.org
 Call (800) 482-4858

