

Association of Technical Personnel in Ophthalmology (ATPO)

CE on the Internet Article

This article and its accompanying quiz are worth .5 JCAHPO Group A continuing education credit.

CONTINUING EDUCATION CREDITS ARE SUBJECT TO CHANGE. Internet Articles are reviewed on a regular basis for content and amount of time needed to complete the article and quiz. We advise you to print the article and take the quiz within 30 days. Ample notice is provided when CE credits change - please check the Web site frequently for any updates and/or changes. We will accept articles for full credit within a 30-day time period when CE credits have changed or when an article has been removed from the Web site.

TREATMENT OPTIONS FOR SUB-FOVEAL CHOROIDAL NEOVASCULAR MEMBRANES PAST, CURRENT

DALE A. NELSON BS, COMT

INTRODUCTION

Advances in health care have dramatically increased life expectancies in the United States and throughout the world. As more of our seniors advance into their 7th, 8th, 9th and even 10th decade of life, eye care professionals are seeing an epidemic of eye diseases which are primarily associated with an aging population.

Now that the first "Baby Boomers" are reaching retirement age, there will be a huge demand for earlier and better treatments and preventive measures for these diseases. Our future "seniors" will be more active than ever and will place a high priority on maintaining excellent levels of visual function.

Exudative adult macular degeneration is the most frequent cause of legal blindness in developed countries. It is estimated that 125,000 new cases per year will develop in the United States alone.

OBJECTIVES

This article will briefly describe the process of choroidal neovascularization (CNV) and it's more commonly seen etiologies. Give an overview of treatment options from both a historical perspective and currently approved methods. Finally, this article will take a look at where the treatment of CNV is headed in the years and decades to come.

THE PAST

Prior to the second half of the 20th century, visual disability due to CNV was much less prevalent than it is today. The fact that eye care was much less advanced and life expectancies were much lower can explain this phenomenon. Simply put, people didn't live long enough to develop this condition.

Choroidal neovascularization is a pathologic condition characterized by the abnormal formation of new blood vessels in the choroid—the vascular layer of the eye between the retina and sclera. Its primary function is to provide nourishment to and eliminate metabolic waste from the outer layers of the retina.

Typically, CNV is seen in a number of ocular diseases, especially Adult Macular Degeneration (AMD), Pathologic Myopia (PM) and Ocular Histoplasmosis Syndrome (OHS). However, any condition where there is a disruption in Bruch's membrane, can lead to a compromise of the choroid's primary functions and lead to increased risk for development of CNV.

Until recently, the most common treatment of leakage from neovascular lesions was laser photocoagulation. In this procedure, the laser energy is converted from coherent light to heat in the choroid. This essentially "spot welds" the lesion, destroying the abnormal leaking blood vessels. The goal of laser photocoagulation was to halt the expansion to the lesion and minimize the size of the resulting scotoma.

Without treatment, CNV is usually self-limiting. However, it is not too uncommon to see arcade-to-arcade disciform scars. These result from CNV that was either left untreated or did not respond well to approved treatments. These unfortunate patients are left with huge and debilitating central scotomas and <20/400 visual acuity.

Laser photocoagulation is a very efficient method of treating CNV, however only about 15 to 20 percent of patients with leakage are candidates for this treatment. Patients with sub-foveal leakage are not candidates because the laser would without doubt destroy any healthy photoreceptors left in the fovea. Also, patients with occult CNV, or neovascularization that is

poorly defined based on fluorescein angiography, are not candidates. With occult lesions the ophthalmologist simply has nothing definite to aim at. There is also a high rate of recurrence with laser photocoagulation.

BETTER TREATMENTS EVOLVE

Since laser photocoagulation had its limitations and drawbacks, the need for better treatment options was essential. Improved technologies that we use today and will use in the future will result from the demands of our ever-expanding aging population and the continued desire of eye-care professional to preserve vision and enhance the daily living experiences of many of our patients. Choroidal neovascularization associated with AMD, PM, OHS and other conditions does not have to be as devastating as it has been in prior decades.

In April of 2000, the FDA approved the use of *verteporfin for injection* under the trade name of Visudyne[®]. This is a drug used with a procedure called *photodynamic therapy* (PDT). It is a light activated drug with a molecular formula of $C_{41}H_{42}N_4O_8$.

Photodynamic therapy consists of two phases. In phase one the Visudyne[®] is administered intravenously using an IV infusion pump over a ten-minute time period. The antecubital vein is preferred. It is transported in the plasma primarily by low-density lipoproteins. After the administration phase, the drug is allowed to concentrate in the neovascular lesion. Due to specific receptor sites in these neovascular membranes, which are not found in healthy vasculature, the Visudyne[®]-LDL complex will rapidly accumulate in any abnormal blood vessels.

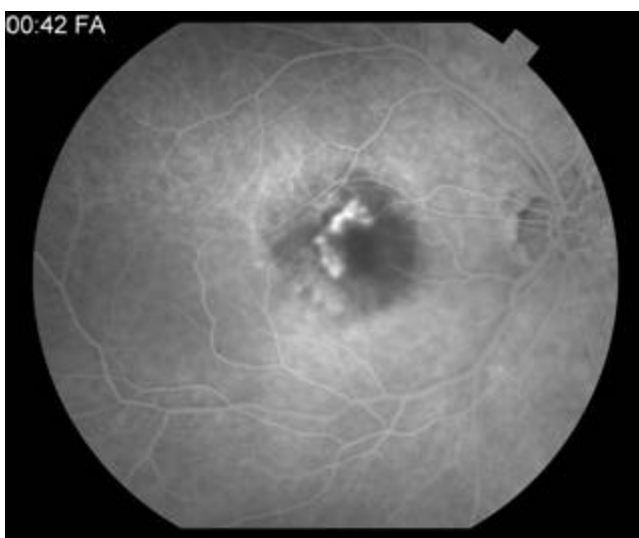
In phase two a non-thermal red laser with a wavelength of 689nm is applied to the area for exactly 83 seconds, fifteen minutes after the start of the infusion. This low energy light activates the concentrated Visudyne[®]-LDL complexes causing a release of oxygen and free radicals. Damage occurs in the vascular endothelial cells of the abnormal vessels resulting in thrombus formation and occlusion of the CNV.

Patients who receive Visudyne[®] will be highly photosensitive. These people are advised to avoid direct sunlight for up to five days. Bright indoor lights such as surgical lights from

operating rooms or dental offices, tanning salons, bright halogen lights, etc need also be avoided. During this post treatment period a person is at risk for severe sunburn and UV blocking sunscreens are ineffective protection against this. Exposure to indoor lighting is encouraged however as ambient indoor light will help inactivate the drug in the skin.

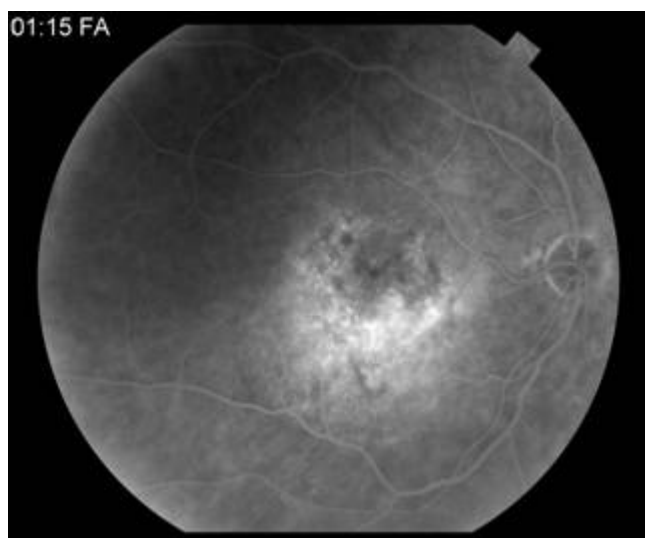
In studies involving AMD patients, those with “classic” or well defined CNV as found on fluorescein angiography who were treated with PDT, showed significantly better results at 12 and 24 months than did those in the placebo group. At 12 months, 67% of those treated with PDT had lost fewer than three lines of Snellen acuity compared to only 43% in the placebo group and at 24 months 59% for Visudyne[®] patients compared to 31% in the placebo group. Severe vision loss defined as $>$ or $=$ 6 lines of acuity from baseline measurements was found in 12% of PDT patients compared to 34% of placebo treated patients at 12 months and 15% vs. 36% at 24 months. Similar results were found in studies involving patient with CNV caused by Pathologic Myopia and Ocular Histoplasmosis.

Retreatment with Visudyne[®]/PDT can take place at 3-month intervals. Fluorescein angiography needs to be repeated at that time to determine the efficacy of prior treatment as well as to determine whether the patient is still a candidate for PDT. Because this treatment uses a non-thermal laser, it is the preferred laser for treatment of sub-foveal or juxta-foveal CNV, especially if they exhibit a predominantly classic membrane. On occult membranes, patients may obtain some benefit from PDT, but not to the extent of those with the classic variety.



Example of “classic” choroidal neovascularization.
Lesion is well defined

Photography by Dale A. Nelson, BS, COMT



Example of “occult” choroidal neovascularization.
Lesion is poorly defined.

Photography by Dale A. Nelson, BS, COMT

ANTI VEGF MEDICATIONS

Vascular endothelial growth factor (VEGF) inhibitors were originally designed to treat solid tumors elsewhere in the body. VEGF is a protein, which in the eye is produced by the retinal pigment epithelium, which stimulates angiogenesis e.g. choroidal neovascularization. The process at least partially depends on the activation of VEGF receptor sites and is achieved by phosphorylation of the receptor using protein kinase C as the catalyst.

Drugs that inhibit protein kinase C can disrupt the process of VEGF mediated angiogenesis. In the case of CNV (classic or occult), these drugs block or turn off the chemical signal necessary for the whole process of neovascularization before the VEGF complex can cross Bruch's membrane.

Pegaptanib sodium injection, trade name Macugen[®], is a VEGF inhibitor injected directly into the vitreous. In vitro testing has shown that this drug binds to the major VEGF form responsible for CNV and prevents it from binding to the receptor sites in the choroid.

In clinical studies, patients with wet AMD were given intravitreal injections every 6 weeks for 48 weeks. The study made no preference to lesion type; classic, occult, or mixed. Statistically, the patients losing less than 15 letters of vision from baseline was 73% for those treated with Macugen[®] vs. 60 % in the placebo group. At the end of one year, most in the original study group were re-randomized to either continue their same treatment or discontinue treatment for the second year. Macugen[®] was found to be less effective after year two, with the percentage of patients losing less than 15 letters from baseline at 57% to 61% with treatment vs. 34% to 56% with placebo, depending on which study you look at the data from.

Most recently, the FDA approved *ranibizumab injection* therapy, trade name Lucentis[™], as a treatment for neovascular AMD. Lucentis[™] is another VEGF inhibitor administered through intravitreal injection. Like other VEGF inhibitors, this drug binds to receptor binding sites,

preventing interaction of VEGF-A with its receptors on the surface of endothelial cells. This action reduces cell proliferation and neovascularization.

In three clinical trials involving Lucentis™, a total of 1323 patients were studied and data compiled for up to 24 months. In studies 1 and 2, the data shows that 95% to 96 % of patients treated with the drug maintained vision, defined as losing fewer than fifteen letters of visual acuity at 12 months from baseline. A considerable proportion of these patients (34% to 40%) had significant improvement, defined as gaining 15 letters of visual acuity at 12 months.

In study number one patients received monthly injections of Lucentis™ for up to 24 months. Data at the end of 2 years show that 90% of patients treated with the drug are still maintaining vision as defined above.

Study number 2 involved various combinations of Lucentis™ intravitreal injections and sham verteporfin PDT, or sham intravitreal injections and active verteporfin PDT. The data suggests that Lucentis™ patients had an average increase in visual acuity of about 11 letters from baseline at 12 months.

Patients in study number 3 received intravitreal injections of Lucentis™ or sham injections monthly for three consecutive doses, followed by doses administered at 3 month intervals. In this study, the Lucentis™ patients had an increase in visual acuity on monthly dosing followed by decrease in acuity when treated every three month. After 12 months, visions had returned to baseline measurements. 90% of these patients maintained there visual acuity at 12 months.

As with any invasive procedure, infection is always a risk. Sterile injection techniques need to be practiced and signs and symptoms of endophthalmitis should be discussed thoroughly with the patient. Post-injection antibiotic drops need to be instilled accordingly for five days. Increased intraocular pressure is also a risk that should be monitored within 30 minutes of injection and managed appropriately.

TREATMENT GOALS

A look at the statistics shows that neither PDT-Visudyne[®] treatment nor Macugen[®] injection therapy provide complete and lasting control of CNV problems. Each treatment option requires multiple treatments during the first two years. PDT averages about five and Macugen[®] averages about nine treatments respectively. Treatment goals are geared toward minimizing the impact of central scotoma development and maintain the maximum amount of useful functioning vision the patient has. Many patients benefit from concurrent low vision evaluations.

Only a small number of patients treated with either PDT-Visudyne[®] or Macugen[®] actually report any noticeable improvement. Of the approved treatments, Lucentis[™] appears to show the greatest potential for significant increase in vision. Statistics from the clinically trials predict this and in our own practice we have found this to be true. While this is great news, patients need to be educated to the fact that the primary goal of any treatment is to stabilize and not improve central vision. This will help to avoid excessively high expectations and consequent disappointment. These are treatments only and do not provide a cure for the diseases that lead to CNV.

THE FUTURE

Ongoing research will soon give ophthalmologists an assortment of other treatment options. Newer uses for the anti-cancer drug *bevacizumab*, trade name Avastin[®] of which Lucentis[™] is an offshoot and Cytochalasin E are being looked at as options for their anti-VEGF properties. Avastin[®] has been used off label for treating CNV as well as neovascularization from diabetic retinopathy. Cytochalasin E, derived from a naturally occurring fungus, is also being researched as an angiogenesis inhibitor. Early evidence shows there may be a better chance for actual improvement in vision with some of these new treatments.

The latest trends for treating CNV involve combination therapies. These use both photodynamic therapy and intravitreal or juxtasclear (sub-tenons) injections of either triamcinolone or one of the anti-VEGF medications. Triple therapy combines PDT, and injections or both a steroid and an anti-VEGF. Early data show that the synergistic effects of

these drugs may be a better treatment than using any one singly. Large clinical trials are now needed to confirm the efficacy of these treatments.

Prophylactic treatments for dry AMD may someday treat this disease before CNV begins. In the PTAMD clinical trial, a gentle “sub-threshold” diode laser is used to reduce the number and size of drusen and hopefully prove that treatment of this type will decrease the development of CNV before visual problems occur.

Genetic researchers have located the first ever gene linked to dry AMD. This defective gene was present in 16% of people with AMD including patients without family history. Genetic testing may someday identify people who are susceptible.

Retinal transplants, or the grafting of “good” retinal tissue into non-working retina, are limited by technologies that currently do not exist. The successful transplant needs cells which must remain alive for a long time, they must have and maintain the light sensing activity of normal, healthy retinal cells and they must transmit electrochemical signals to the brain for processing and interpretation. Retinal implants, prosthetic retinas and “computer vision”, are currently in the realm of science fiction and like retinal transplants, will need many years to develop successful technologies in these areas.

Perhaps the most exciting and fascinating area of research deals with retinal cell regeneration. Historically, eye care personnel had no choice but to tell patients and their families that nothing could be done to restore lost vision. The advent of the age of stem cells has changed that.

Research reported as early as May of 2000 suggested that neural stem cells injected into the sub-retinal space in rats, could be stimulated into growing into macular photoreceptors. Others injected neural stem cells into the vitreous. Under highly controlled conditions, these cells migrated to the retina and changed into photoreceptors as well.

Embryonic stem cells transplanted into the sub-retinal space, were also shown to develop into light sensing cells.

Now for the first time, we can see hope on the horizon, that someday the devastating effects of CNV and the implications for our senior citizens may be reversible.

PREVENTION

As with many chronic conditions, there are factors that we have no control over. However there is mounting evidence that certain life-style changes and behavior modifications can minimize the risk from factors that we can control.

Smokers are at significant higher risk for developing AMD. There was also little reduction in risk even 15 years after a person quits smoking. One pack a day smokers have a 2 to 3 times greater risk for AMD compared to those that have never smoked. As with other smoking related diseases, second hand smoke is still a danger.

Other factors include high blood pressure, possibly high blood sugar in diabetes, elevated cholesterol and obesity (especially in men). It also seems that the very leanest are at some increased risk as well.

A diet high in carotenoids such as lutein and zeaxanthin were shown to reduce the risk of developing AMD. These nutrients are commonly found in leafy green vegetables. Spinach, collard greens, kale etc eaten at least five times a week had the greatest impact. Apparently, anti-oxidants in these compounds enter the eye and selectively accumulate in the retina where they filter out visible blue light that can damage the macula over time. Regular use of UV and blue blocking sunglasses will also help.

SUMMARY

Choroidal neovascularization due to adult macular degeneration is currently the leading cause of blindness in the United States. Past and current treatments have focused on treating patients after problems have occurred and have offered little hope for improvement. Exciting research is giving new hope for better treatment and even reversal of this disease and other similar conditions. In the future, our patients may never need a low vision exam, or be forced to surrender their driving privileges as they live longer, more active, healthier lives.

REFERENCES

Cassin, Barbara and Solomon, Sheila A.B., Dictionary of Eye Terminology Third Edition, Triad Publishing Company, Gainesville, FL, 1997.

www.eyesight.org, Internet website article, Adult Macular Degeneration, David Seftel, MD.

Ibid, Photodynamic therapy: An Emerging Treatment for Classically Leaking Neovascularizations, Philip Filner, Ph.D.

Visudyne® package insert, Novartis Pharmaceuticals, Inc., Sept. 2004.

Macugen® package insert, Pfizer Pharmaceuticals, Inc., Dec. 2004.

Lucentis™ package insert, Genentech, Inc., June 2006.

www.eyesight.org, Internet website article, Protein Kinase C: Possibly a Drug Target for Inhibiting Neovascularization in Wet Age-related Macular Degeneration, Philip Filner, Ph.D.

Ibid, Cytochalasin E-Angiogenesis Inhibitor, National Institute of Health, Aug. 2003.

Ibid, PTAMD Clinical Trial for “Dry” AMD.

Ibid, Gene Tied to Dry Form of Adult Macular Degeneration, Press Release from National Institute of Health, Sept. 18, 1997.

Ibid, Retinal Transplants and Implants, Philip Filner, Ph.D.

Ibid, As Therapy for Macular Degeneration, Regenerating Retinal Cells Moves Several Steps Closer to Reality, May 5, 2000, Fort Lauderdale, FL.

Ibid, Smoking Increases Risk of Macular Degeneration, Journal of the American Medical Association press release, Oct. 9, 1996.

Ibid, Body Mass Index and the Incidence of Visually Significant Age-related Maculopathy in Men, published Feb. 12, 2001.

Ibid, Diets High in Carotenoids May Lower Risk of Macular Degeneration, from reprint of Medical Science Bulletin, Pharmaceutical Information Associates, Ltd., Feb.1995.

Ryan, Edwin H., The Role of Verteporfin Photodynamic Therapy in Current Therapy for Exudative Age-related Macular Degeneration. US Sensory Disorders, 2006.

TREATMENT OPTIONS FOR SUB-FOVEAL CHOROIDAL NEOVASCULAR MEMBRANES PAST, CURRENT

This article and accompanying quiz are worth .5 JCAHPO Group A continuing education credit.

You must complete the enclosed quiz on your own and may not seek assistance from other individuals in completing the quiz. You may, however, seek assistance from other individuals for clarification and understanding of the article content. Failure to comply with this policy may result in the revocation of credit.


1. The leading cause of blindness among senior citizens in the United States is
 - a. Diabetic retinopathy
 - b. Adult macular degeneration
 - c. Choroidal melanoma
 - d. Ocular histoplasmosis syndrome
 - e. Strabismus

2. A disruption in Bruch's membrane from pathologic myopia can lead to
 - a. Corneal edema
 - b. Cystoid macular edema
 - c. Diabetic retinopathy
 - d. Choroidal neovascularization
 - e. Thick glasses

3. Twenty years ago, the best treatment for sub-foveal neovascularization was
 - a. no treatment
 - b. Macugen[®] injection therapy
 - c. Laser photocoagulation
 - d. Photodynamic therapy
 - e. Lucentis/PDT combination therapy

4. In photodynamic therapy, the Visudyne[®] drug is transported to the retina primarily by:
 - a. Anti-oxidants
 - b. Low density lipoproteins
 - c. Electric conduction
 - d. VEGF
 - e. UPS

5. Which statement is true of photodynamic therapy?
- It is most successful with “classic” CNV.
 - Visudyne® accumulates to a greater degree in abnormal blood vessels.
 - A non-thermal red laser with a wavelength of 689 nm is applied for 83 seconds.
 - The laser energy activates the medication.
 - All of the above are true.
6. Which statement is not true of photodynamic therapy?
- Treated patients have sunlight restrictions for up to five days.
 - PDT can be repeated at three month intervals.
 - After PDT, the patient needs to instill antibiotic drops for five days.
 - PDT does not work as well on “occult” CNV, as it does on the “classic” type.
 - The Visudyne medication enters the bloodstream thru an IV infusion.
7. Which statement is true of Lucentis™ injection therapy?
- Lucentis™ is a vascular endothelial growth factor (VEGF) inhibitor.
 - About 35% to 40% of Lucentis™ treated patients have significant improvement in visual acuity.
 - Lucentis™ is injected into the vitreous.
 - Lucentis™ is used for treating all forms of CNV.
 - All of the above are true.
8. Which statement is true of the PTAMD study?
- It is studying the prophylactic treatment of dry AMD.
 - It uses newer varieties of anti-VEGF drugs.
 - It uses retinal implants.
 - It treats drusen with a diode laser.
 - Both a and d above.
9. Retinal transplants, implants and “computer vision” are
- Very successful procedures.
 - Currently in the realm of science fiction.
 - Already being successfully performed in other parts of the world.
 - Can be done on an out patient basis.
 - None of the above.

10. Which is true regarding retinal regeneration?
- a. Research is illegal because of political and ethical reasons.
 - b. Stem cell injection therapy will be FDA approved in July of 2006.
 - c. Both neural and embryonic stem cells have shown promise in research done on rats.
 - d. Stem cells need to be activated using a sub-threshold red laser.
 - e. Stem cell implantation is part of a triple therapy regimen.
11. Risk factors for developing AMD include:
- a. High blood pressure
 - b. Smoking
 - c. Obesity, especially in men
 - d. Having a defective gene which is linked to dry AMD
 - e. All of the above
12. A diet that will reduce the risk of AMD would include:
- a. Cheerios and skim milk
 - b. Dark chocolate
 - c. Steel-cut whole wheat bread
 - d. Spinach and collard greens
 - e. A combo meal at McDonalds
13. Risks involved in treating CNV can include:
- a. Endophthalmitis with Macugen[®] injection treatment
 - b. Bad sunburn with photodynamic therapy
 - c. Meibomian gland dysfunction
 - d. Both a. and b.
 - e. None of the above
- 

TREATMENT OPTIONS FOR SUB-FOVEAL CHOROIDAL NEOVASCULAR MEMBRANES PAST, CURRENT

Internet Answer Sheet

This article and accompanying quiz are worth .5 JCAHPO Group A continuing education credit.

You must complete the enclosed quiz on your own and may not seek assistance from other individuals in completing the quiz. You may, however, seek assistance from other individuals for clarification and understanding of the article content. Failure to comply with this policy may result in the revocation of credit.

Name _____ JCAHPO Certification _____

Home Address _____

City / State / Zip _____

Home Phone _____ Work Phone _____

E-mail Address _____ Signature _____

PAYMENT INFORMATION - ALLOW 2-4 WEEKS FOR PROCESSING

Price (check one)

- ATPO Member – \$8
- ATPO Member – Complimentary*
- Non-Member – \$12
- Rush Processing - \$10.00

***ATPO members receive 4 complimentary CE credits via CE on the Internet or COVE assessment exams.**

Method of Payment: Check (payable to ATPO) VISA MasterCard Discover Am. Express

Credit Card #: _____

Expiration Date: _____ Security (SVC) Code (on back of credit card): _____

Name of Cardholder (please print): _____

Cardholder's billing address: _____

Cardholder's Signature: _____

Place your answers to each question in the appropriate space adjacent to the question number.

- | | | |
|----------|-----------|-----------|
| 1. _____ | 6. _____ | 11. _____ |
| 2. _____ | 7. _____ | 12. _____ |
| 3. _____ | 8. _____ | 13. _____ |
| 4. _____ | 9. _____ | |
| 5. _____ | 10. _____ | |

By filling in the above spaces and signing your name, you agree that:

- A total of 75% or more correct is a passing score.
- ATPO is not responsible for Answer Sheets and Evaluation Forms not received at the ATPO offices.

I attest that I have completed this quiz on my own.

(SIGNATURE)

Return completed answer sheet, evaluation form, and payment to:

ATPO
Attn: CE Dept
2025 Woodlane Drive
St. Paul, MN 55125
Fax: (651) 731-0410

Questions?
Visit www.atpo.org
Call (800) 482-4858



Office Use Only

Date Exam Received _____

Date Exam Scored _____

Score _____ Pass Fail

CONTINUING EDUCATION CREDITS ARE SUBJECT TO CHANGE. Internet Articles are reviewed on a regular basis for content and amount of time needed to complete the article and quiz. We advise you to print the article and take the quiz within 30 days. Ample notice is provided when CE credits change - please check the Web site frequently for any updates and/or changes. We will accept articles for full credit within a 30-day time period when CE credits have changed or when an article has been removed from the Web site.

CE on the Internet Evaluation

TREATMENT OPTIONS FOR SUB-FOVEAL CHOROIDAL NEOVASCULAR MEMBRANES PAST, CURRENT

Please read each question carefully. Your feedback is **important** to us. Thank you!

1. How long have you been employed in the field of ophthalmology? _____ years
2. This written article was designed at a level right for me. (*circle one*) YES NO
3. Please read the following statements. Then, circle the number corresponding to the degree to which you agree with each statement.

Statement	Strongly Agree	Agree	Disagree	Strongly Disagree	Not Applicable
a. The material was organized and presented in a clear and efficient way.	5	4	3	2	1
b. The information will be useful/relevant to me.	5	4	3	2	1
c. The material was presented at a level appropriate to my background and level.	5	4	3	2	1
d. Overall, I was satisfied with the article.	5	4	3	2	1

4. What part of the article was **most useful** to you?

5. What part of the article was **least useful** to you?

6. What suggestions do you have for improving this article?

Thank you for completing this article evaluation! ATPO values your feedback. Please return your evaluation form with the completed quiz and payment.

Return completed answer sheet, evaluation form, and payment to:

ATPO
 Attn: CE Dept
 2025 Woodlane Drive
 St. Paul, MN 55125
 Fax: (651) 731-0410

Questions?
 Visit www.atpo.org
 Call (800) 482-4858

